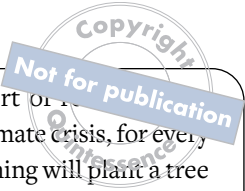




The Art of Complete Culture Therapy  
for the General Practitioner



One book, one tree: In support of environmental conservation worldwide and to address the climate crisis, for every book sold Quintessence Publishing will plant a tree (<https://onetreepanted.org/>).



### Library of Congress Cataloging-in-Publication Data

Names: Huff, Kevin, author. | Benting, Douglas, author.

Title: The art of complete denture therapy for the general practitioner / Kevin Huff, Douglas Benting.

Description: Batavia, IL : Quintessence Publishing Co, Inc, [2022] |

Includes bibliographical references and index. | Summary:

“Systematically details each clinical and laboratory step in the process of fabricating complete dentures, from examination and patient selection to maintenance procedures after treatment”-- Provided by publisher.

Identifiers: LCCN 2021008345 (print) | LCCN 2021008346 (ebook) | ISBN 9780867159677 (hardcover) | ISBN 9781647240868 (ebook)

Subjects: MESH: Denture, Complete | Denture Design | Dental Models | Mouth, Edentulous

Classification: LCC RK656 (print) | LCC RK656 (ebook) | NLM WU 530 | DDC 617.6/92--dc23

LC record available at <https://lcn.loc.gov/2021008345>

LC ebook record available at <https://lcn.loc.gov/2021008346>

A CIP record for this book is available from the British Library.

ISBN: 9780867159677



© 2022 Quintessence Publishing Co, Inc

Quintessence Publishing Co, Inc

411 N Raddant Road

Batavia, IL 60510

[www.quintpub.com](http://www.quintpub.com)

5 4 3 2 1

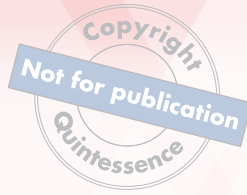All rights reserved. This book or any part thereof may not be reproduced, stored in a retrieval system, or transmitted in any form or by any means, electronic, mechanical, photocopying, or otherwise, without prior written permission of the publisher.

Editor: Marieke Z. Swerski

Design: Sue Zubek

Production: Sarah Minor

Printed in Croatia



# The Art of COMPLETE DENTURE THERAPY

## for the General Practitioner

**Kevin D. Huff, DDS**

Private Practice  
Dover, Ohio

**Douglas G. Benting, DDS, MS**

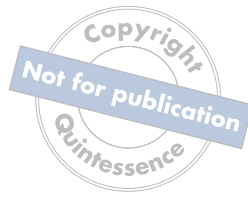Private Practice  
Phoenix, Arizona

With contributions by

Gary M. DeWood, DDS, MS, Margaret Frankel, DMD, & Rick Jude, DMD

 **QUINTESSENCE PUBLISHING**

Berlin | Chicago | Tokyo  
Barcelona | London | Milan | Mexico City | Moscow | Paris | Prague | Seoul | Warsaw  
*Beijing | Istanbul | Sao Paulo | Zagreb*

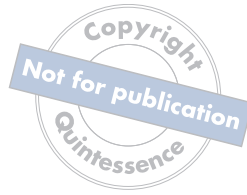

“ This book is dedicated to my mother, Marlene Huff, RN, PhD, who has been my first mentor and role model for ethical patient care as well as my advisor, counselor, and lifelong cheerleader and friend. It is also dedicated to my many mentors, past students, and trusted colleagues who have encouraged me throughout my career and taught me much more than I can remember. It is also dedicated to my father, Darryl, who took up a second career upon retirement from being a school principal to work with me as my in-house laboratory technician; it was an honor to train him in the laboratory skills discussed in this text and then to refine my own skills in collaboration with him. Lastly, but certainly not in the least, this work could not have been completed without the support and encouragement of my wife Stacie and my daughter Kamdyn.

*Kevin D. Huff*

“ The gratitude that I feel for being a part of a profession connected with continuous learning is incredibly energizing, and I cannot imagine this life experience without the interaction with many willing and unknowing mentors that have had influence over time—thank you all for being there! This book is a representation of the support I have been fortunate to receive from my family unit, my parents Gary and Laurel as well as my wife Gwen and daughter Isabella. Thank you for your presence and your grace!

*Douglas G. Benting*



# CONTENTS

Foreword *vi*

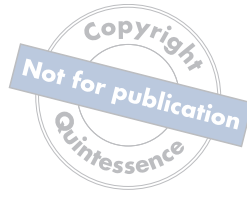Preface *viii*

How to use this book *x*

- 1 Understanding the Art of Complete Denture Therapy 1
- 2 Examination 11
- 3 Impression Technique 49
- 4 Fabrication of Master Casts and Record Bases 67
- 5 Occlusion and Esthetics 89
- 6 Behind the Scenes in the Dental Laboratory 141
- 7 Delivery 151
- 8 Transitioning to Complete Edentulism 161
- 9 Maintaining Excellence: Reline, Rebase, Repair 183

Index 203

# FOREWORD



When my friend for more than two decades, Kevin Huff, invited me to write the foreword for his new book on complete denture therapy, I was excited for many reasons, not the least of which is to witness—decades later—how the love of removable prosthetic therapy that I first observed when he was a dental student has grown throughout his career as a clinician. More pragmatically, as a dental educator, researcher, and prosthodontist, I believe that a contemporary and practical book for the general practitioner and for the dental student is long overdue. Dr Huff collaborated with Douglas Benting, a practicing prosthodontist in Phoenix, Arizona, to produce a modern book on contemporary complete denture therapy that is written in a scientific yet practical way, addressing the issues that may appear in everyday clinical practice. Both authors combine decades of experience as practitioners in the real world and as educators to dental students and practicing dentists to bring back to life an art that appears to be dying in a world where implant-supported prostheses dominate. In fact, there are many people who suffer from the handicap of edentulism for whom dental implants are contraindicated for a variety of reasons (eg, anatomical limitations, financial challenges). This textbook clearly illustrates the zeal that Drs Huff and Benting have about educating as many clinicians in the art of complete denture therapy as are willing to learn while empathetically addressing patient needs through demonstrating a method to follow the code of ethics as prescribed by Hippocrates.

Through this book, Drs Huff and Benting highlight the importance of key ethical tenets: patient autonomy, nonmaleficence, benevolence, justice, and veracity. It is common for clinicians to minimize the importance of (and sometimes to forget) the ethical treatment of patients who suffer from edentulism who may not be able to undergo dental implant therapy. Unfortunately, there may be a tendency to minimize the importance of complete denture therapy to “just plates” rather than a medical device that can greatly improve and even extend a patient’s life. When complete dentures are viewed as commodities rather than life-changing prostheses for those suffering from total edentulism, corners are often cut for financial gain. Drs Huff and Benting have provided a valuable refresher on the

importance of empathy and the application of dental ethics to complete denture therapy that hopefully will encourage the reader to fight this trend.

For example, through case examples and ethical decision-making sidebars, the authors emphasize that the patient must be informed about the available treatment options for their condition and have the knowledge available to decide their appropriate course of treatment while understanding the risks and benefits of their choice. Especially, the patient in a terminal dentition state has to be ethically guided to make the right decision on whether effort should be taken to save the remaining teeth, extract them and fabricate a complete denture, or extract them and fabricate an implant-supported prosthesis. Additionally, the authors highlight the fact that the general practitioner needs to be self-aware and be able to understand when to refer the patient to a more qualified specialist.

While the rates of edentulism are declining in industrialized countries, the need for quality complete denture therapy will be substantial for a long time to come due to population aging, migration, and fiscal issues. Even if a patient is going to receive full-mouth implant-supported prostheses, all the preliminary work to define the proper vertical dimension, jaw relation, occlusal plane, lip and cheek support, position of maxillary central incisor, and phonetics and esthetic evaluation should be accomplished with the tools taught in complete denture fabrication. Therefore, understanding the art of complete denture therapy is essential even for those clinicians who primarily provide fixed or fixed-detachable implant prosthetic therapy.

This book has been structured in a pragmatic manner that walks the reader through the actual dental appointment workflow: examination, initial impressions, custom tray fabrication, final impressions, master casts and base plate fabrication, tooth selection and esthetic try-in, dental laboratory procedures, delivery, remount procedures, and maintenance. Alternative methods to minimize the number of clinical appointments are not forgotten nor dismissed by Drs Huff and Benting, and related reasonable approaches are described and discussed. Because some clinicians enjoy laboratory work and others prefer to outsource as much



laboratory work as possible, the authors review laboratory steps that can easily and practically be done in house. Of course, each clinician must decide to what extent they will be involved in the nonclinical stages of denture fabrication, and the authors provide valuable assistance in making this decision.

A great effort was put into presenting the concept of digital technology in complete dentures. However, this area of complete denture therapy is in its infancy at the time this book is written. Therefore, current challenges and benefits as we currently understand them are skillfully presented while the authors are fully aware that as technology improves, the information presented regarding digital denture therapy may rapidly change. With the advent of new digital technologies, the practitioner has more available tools that can potentially benefit the patient as we move into the future. Since these technologies are continually evolving, we should continue exploring them and judiciously decide what should be incorporated in our daily workflow.

Complete denture fabrication is the basis of advanced prosthetic therapy. This book will help dental students to be taught complete dentures in a new fresh way. Additionally, it is worth reading and it will assist general practitioners who may have a desire to master complete denture therapy while elucidating some of the secrets of complete denture therapy.

**Efstratios “Stratis” Papazoglou, DDS, MS, PhD**

Associate Professor  
Department of Operative  
Dentistry  
School of Dentistry  
National and Kapodistrian  
University of Athens  
Athens, Greece



# PREFACE



Despite remarkable advances in technology and oral medicine that allow for earlier diagnosis, predictable treatment outcomes, and less invasive treatment, tooth decay and periodontal disease continue to be major causes of tooth loss in the aging population. As the worldwide population of those over the age of 50 years continues to grow—and is expected to continue growing over the next two to three decades—the need for quality denture care is becoming increasingly important. Practicing clinicians are faced with the challenging task of managing complete edentulism for this aging population. However, there is a recent trend in undergraduate dental education to reduce the time spent on the basic principles of removable complete denture therapy. While the ever-growing scientific knowledge about the field of general dentistry demands increasing focus on other areas of dental education (eg, CAD/CAM and digitized workflow, orofacial pain, oral medicine, implant therapy, etc) to keep pace with modern knowledge and to prepare dentists for the skill sets that they need now and going forward, removable complete denture therapy is one of the areas that cannot be forgotten. As we, the authors, have personally witnessed—and has many of you have expressed to us at various venues and through social media—a significant segment of the edentulous population, already forced to live without teeth, must also live with inadequate dentures. Removable complete denture therapy is often performed by clinicians, general dentists, and even denturists whose limited training prevents them from delivering the high quality of care required for this population. While there is a trend and a common belief—possibly even a mantra—that dental implants are a panacea for edentulous patients, we strongly believe that complete denture therapy remains a valid option for providing a reasonable quality of life for many in the edentulous population, as long as basic principles are mastered in conjunction with it.

Our experience working with undergraduate dental students as well as many practicing dentists who take continuing education workshops has made it clear to us that many general practitioners believe they have been adequately trained in complete denture therapy in dental school, but they admit that they may only have completed

a complete denture for a single arch prior to beginning private practice. However, the first patient who does not present as a textbook-like case highlights their lack of understanding of many nuances of complete denture therapy, such as the patient who does not have a stable and reproducible biting position, who is psychologically compromised, or who has severe ridge atrophy. Many of these topics regarding denture care have been removed from basic complete denture training in dental schools in the past two decades due to time constraints in dental school curricula. However, they are essential for practicing clinicians to manage moderately complex and difficult cases that are routinely encountered in daily clinical practice. Unfortunately, many clinicians who choose to provide complete denture therapy default to relying on commercial laboratory technicians for key diagnostic skills like occlusal design and tooth position that approximate appropriate anatomy for each individual patient. When clinicians become frustrated with the results and patient disgruntlement that may occur because of inadequate training and diagnostic skills for complete denture therapy, many choose to give up and stop providing this valuable service, especially since continuing education is limited for complete denture therapy. Some even view this therapy as a lower-producing service. However, the principles of identifying tooth position, working with both intra-oral as well as extraoral landmarks in complete denture therapy, are fundamental to the positioning and placement of dental implants. Elaborate planning for complex implant-supported prostheses without first mastering the art of complete denture therapy is, quite frankly, getting the care before the horse, so to speak.

There have been several excellent textbooks written on complete denture therapy. However, a book dedicated to removable complete denture therapy has not been published in the past decade. Those books that started out being dedicated to removable complete denture therapy have followed suit with dental education trends and have become filled more and more with dental implant prosthetics while minimizing the basic tenets of removable complete denture therapy that we strive to highlight here. Since many basic principles of complete denture therapy





## ACKNOWLEDGMENTS

(eg, border molding and impression making, in-laboratory denture processing) have been thoroughly discussed in other texts, our goal has been to provide a review of those concepts through photographic essays. In other areas of interest, such as examination of the complete denture patient and smile design, we have gone in depth to illustrate the fact that there is still a person who wears the complete dentures—with many of the needs of the dentate patient and who may present with greater diagnostic challenges.


A key point that we strive to make throughout this book is that complete dentures are not a replacement for teeth; they are a substitute for no teeth. They do not function nor feel anything like natural teeth. If we believe this, then we also must recognize that modern complete denture patients deserve to be treated by clinicians who have current diagnostic skills, including airway considerations, conditions affecting the temporomandibular joints and denture support structure, and esthetic smile design principles. Therefore, in this book we address the concepts of ethical and evidence-based treatment planning, understanding that complete denture therapy may realistically be a transitional step to more advanced dental prosthetics.

We are passionate about the need for quality removable complete denture therapy and are empathetic to the needs of those who suffer from the loss of teeth yet cannot enjoy the benefits of implant-supported prostheses for a variety of reasons. Therefore, the primary objective of *The Art of Complete Denture Therapy for the General Practitioner* is to present realistic methods and techniques to practicing dental practitioners for providing quality removable complete denture therapy from the perspective of a practicing general dentist. Our goal for this book is to provide an interactive reference of best practices for practicing dentists and other clinical care providers who desire to serve the edentulous population through quality removable complete denture therapy.

We are extremely grateful for the meaningful contributions of our authors. Dr Gary DeWood brings a modern and well-founded method of esthetic smile design to life based on the fundamental concept of artistically positioning teeth in harmony with facial anatomy. Dr Margaret Frankel summarizes what we currently understand about the airway, especially how it relates to the edentulous population. We would also like to extend our warmest gratitude to Dr Rick Jude, the prosthodontist who originally wrote the core manuscript upon which this textbook was founded. Without his ongoing support and consultation, this book would not have been possible. Of course, we are also grateful to Dr Efstratios “Stratis” Papazoglou, who has given his time and energy to comment on and review this text.

There are two commercial dental laboratories who have graciously contributed photography and offered technical advice for this text. Bay View Dental Laboratory in Chesapeake, Virginia, is a full-service commercial dental laboratory who has built a solid reputation for quality dental prosthetics ([www.bvdl.com](http://www.bvdl.com)). Lantz Dental Prosthetics, Inc, in Maumee, Ohio, is a commercial laboratory dedicated to the quality fabrication of removable partial dentures, implant-supported dentures, and removable complete dentures ([www.lantzdental.com](http://www.lantzdental.com)). We thank these laboratories for their contributions to this book.

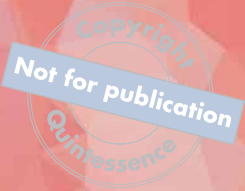Lastly, but certainly not least, we thank our wives and children for allowing us the time to spend on this project. Their support and encouragement have helped us fight writer’s fatigue, provided ideas for creativity, and allowed us to manage the challenges of writing a textbook. To them we say, “Thank you. You are very special to us, and we love you.”



# HOW TO USE THIS BOOK

For easy reference, we have identified each step in the complete denture therapy process according to clinical and laboratory steps. Throughout this book, you will find color-coded page markers identifying clinical steps, laboratory steps, and digital solutions. We hope that you will find this format helpful as you master complete denture therapy in your practice.

Standard Sequence of Complete Denture Therapy		
CLINICAL APPOINTMENT STEPS	LABORATORY STEPS	PAGE
Examination, imaging, and preliminary impressions		11
	Custom tray fabrication	55
Final impressions		59
	Boxing and pouring	67
	Baseplate and wax rim fabrication	76
Jaw records		94
	Mounting models on an articulator	116
	Setting prosthetic teeth and preparing wax-up	120
Esthetic try-in		134
	Flasking, processing, remounting, grinding in occlusion, finishing, and polishing	142
Delivery		154
Clinical remount (may be done at delivery)	Clinical remount (may be done at delivery)	152
Follow-up adjustments		156



## Chapter 1

# Understanding the Art of Complete Denture Therapy

*I don't do many dentures, but when I do, success is a total crapshoot. At this point, I'm seriously considering sending all of my dentures down the road to one of the chain practices that do a lot of dentures, or I need some serious enlightenment on how to make a great denture. No matter how much adjusting, soft liners, or hard relines I make, I still can't make my patients comfortable. I'm losing patients, and I'm losing money. Worse yet, I'm starting to hate doing dentures!*

*–Paraphrased from discussions with a “millennial” dentist*

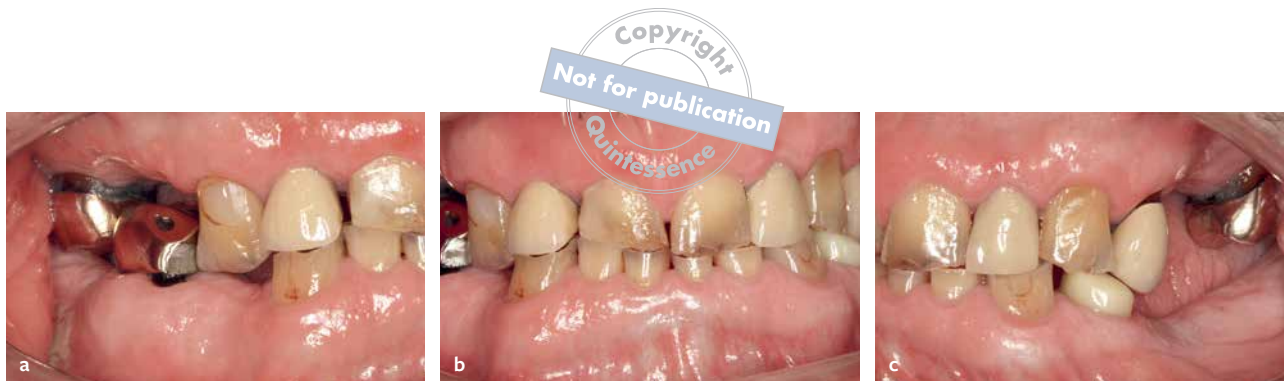## Is Complete Denture Therapy Still Relevant?

---

Complete denture therapy remains a valid option for providing a reasonable quality of life for the edentulous population. The worldwide population of those over the age of 50 years is expected to continue to grow over the next two to three decades, and despite remarkable advances in technology and oral medicine that allow for earlier diagnosis, tooth decay and periodontal disease continue to be major causes of tooth loss in the aging population. As a result, predictable treatment outcomes, less invasive treatment, and the need for quality denture care will become increasingly important. However, there is a recent trend in undergraduate dental education to reduce the time spent

on complete denture therapy techniques while increasing focus on other areas of dental education to keep pace with modern technology and increased demand for focus on dental medicine. While attention to these areas of dental education is essential, a significant segment of the edentulous population may be restricted to complete denture therapy provided by clinicians who are inadequately prepared to meet their basic needs. Specifically, while dental implant therapy is a valuable service and requires adequate training to meet appropriate standards of care, implants are still out of the realm of possibility for many patients for a variety of reasons (eg, financial limitations, anatomical limitations, medical contraindications).

In the United States, the National Health and Nutrition Examination Survey (NHANES) estimates that among people from 65 to 74 years of age, 23.93% are completely edentulous. Of those who are 75 years or older, over 31% are missing all teeth.<sup>1</sup> While it is generally accepted that the percentage of adults who are edentulous is decreasing, this is somewhat offset by the increasing number of people living past the age of 65 in the United States. Given these statistics, we believe that providing quality complete denture services should be mastered and considered essential. Unfortunately, complete denture therapy training tends to be progressively diminishing in dental school and continuing education curricula to be replaced by increased training in the field of fixed implant prosthodontics. Since understanding the biophysics and functional esthetic principles of complete denture therapy is essential to advanced therapy with dental implants, we hope that the concepts of this text are studied and implemented in general practice.



**FIG 1-1** (a to c) Case example 1. A patient with a severely worn dentition presents requesting full-mouth exodontia and complete denture therapy. →

We have spoken with many general dentists over the years who feel that the level of patient satisfaction with complete dentures is just too low to justify the amount of time required to provide premium services. In addition, the value of complete denture therapy is increasingly minimized through a constant drive by third-party payers, the corporate marketplace, and by patient misconception, resulting in reimbursement rates and fee design that simply fail to make denture therapy profitable for many clinicians. We firmly believe that the success rate for denture therapy, including clinician and patient satisfaction, can be much higher than is generally experienced. The prerequisite for success is for the therapy to be done properly—which includes resisting the temptation to cut corners during construction of complete dentures—while charging ethical and reasonable fees commensurate with the time spent and expertise of the clinician providing the therapy.

In the pages that follow, our goal is to provide an interactive reference for general dentists who desire to serve the edentulous population through quality removable complete denture therapy. It is not our intention to minimize the benefits of nor to discredit implant dentistry but to simply provide a foundation for an alternative approach. Complete denture therapy, in our opinion, is also foundational to being able to provide excellent complex dental therapies, including implant-supported reconstruction.

## How to Help Your Patients Decide if Complete Dentures Are Right for Them

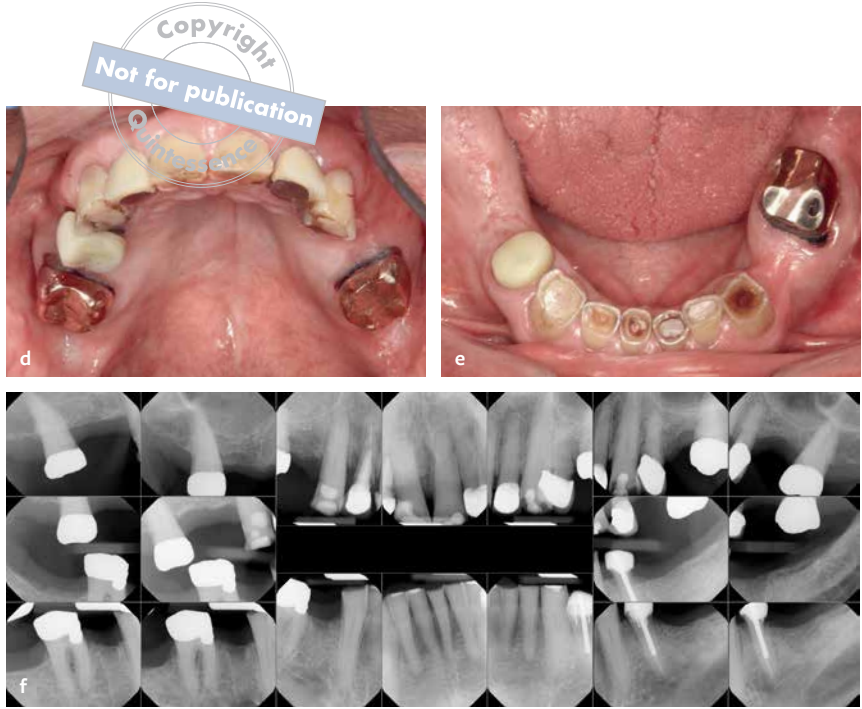
Throughout our discussions with you, we will be applying ethical decision-making principles in an effort to assist you in making choices regarding diagnoses and technical procedures. While we fully understand that you may not

agree with our ethical arguments, we hope and trust that they will stimulate your thought processes along the way toward excellent denture care.

For example, consider the following case: A 73-year-old man who has a very public persona presents to your office with the vague chief complaint of “My teeth are breaking, and I want dentures.” He states that he has no significant financial limitations. His medical history is positive for coronary bypass within the past 5 years without complications, type 2 diabetes mellitus, and two-a-day cigar smoking for over 40 years, and he is taking anticoagulant medications. His dental history, as might be obvious from his clinical presentation, reflects a lifelong history of problem-focused dental care with a poor recall compliance history. The clinical exam reflects a nonrestorable and abscessed maxillary right lateral incisor, generalized attrition and compensatory eruption, no active caries, and no periodontal pocketing beyond 3 mm. An ethical decision-making process must be exercised before the question can be answered, “What should you do?” (Fig 1-1).

Applying an objective ethical decision-making process to this case would assist in developing an appropriate care plan<sup>2</sup> (Table 1-1). In this process, we would carefully weigh the possible treatment options in light of five ethical principles: patient autonomy, nonmaleficence, beneficence, justice, and veracity. As clinicians, we have a duty to respect our patient’s right to decide their own course of treatment; however, this choice cannot be made without a thorough understanding of the reasonable risks and benefits of that choice. We also have a duty not to intentionally hurt our patients, including performing treatment that we know will leave them in worse condition than their initial presentation or with a higher risk of expense, discomfort, and inconvenience. Along those same lines, the principle of beneficence demands that we have a duty to promote the well-being of our patients, which may include enabling increased self-esteem as well as setting

**FIG 1-1 (CONT) (d to f)** Case example 1. A patient with a severely worn dentition presents requesting full-mouth exodontia and complete denture therapy.



**Table 1-1 Ethical decision-making considerations for Case 1**

Autonomy	Options to be considered included (1) full-mouth reconstruction, (2) accommodative simple dentistry to maintain dentition with extraction and replacement of the failing maxillary lateral incisor, (3) maxillary phased complete denture therapy with or without implant support over mandibular reconstruction with or without single-tooth implants, (4) complete denture therapy, and (5) complete exodontia with complex immediate implant reconstruction. Benefits and risks, including loss of proprioception, bone resorption, medical complications, relative fees, and long-term anticipated maintenance costs, need to be clearly presented to the patient. Only then can he make an informed decision for care.
Nonmaleficence	The patient would best benefit from saving the majority of his existing dentition in order to preserve bone, improve mastication through proprioception, and minimize the medical risks of full-mouth exodontia. Long-term maintenance costs may likely be lower by restoring the natural dentition than the other options. Exodontia with or without implant therapy would require reduction of healthy crestal cortical bone to create prosthetic space.
Benevolence	There is no apparent medical or dental health benefit to extracting any more teeth than the maxillary right lateral incisor. This patient's periodontal status is healthy, and he has excellent bone support for his dentition. The prognosis of a full-mouth reconstruction would be good if performed by an adequately trained clinician.
Justice	Because the patient states that he is not limited financially and cites no significant time constraints, there is no justification for anything but a full-mouth reconstruction of the natural dentition. All of the other reasonable options have compromises to the patient's health and well-being that are unjustifiable. Even if the patient desires complete exodontia, the clinician may be at risk of battery because willfully crippling a patient is not something to which a patient can legally consent.
Veracity	All reasonable options with risks and benefits must be clearly discussed with the patient, and the patient's questions must be answered truthfully. It is the clinician's duty to express the benefits of maintaining the natural dentition in this particular case, and consideration should be given to referral to a prosthodontist if the primary clinician is not appropriately trained to diagnose and manage a case such as this.

**Box 1-1 Influential factors for complete denture prognosis**

- Patient expectations
- Expectations of the patient's significant other(s)
- Previous complete denture history
  - What was successful?
  - What was not successful?
- Anatomical challenges
  - Are there any epuli (hyperplastic tissues)?
  - What is the extent of ridge resorption?
  - Is there a significant skeletal overbite, underbite, or crossbite?
  - Is there an abnormal gag reflex?
- Patient attitude
  - Does he or she value new complete denture therapy?
  - Is the patient requesting care because he or she wants it or because someone else wants them to have it?
- Personality compatibility between the patient and the clinician
- Financial considerations
- Patient selection
- Clinician confidence

the stage for improved physical health through care that we render. The principle of justice demands that we treat our patients fairly, as we would our own friends and families, independent of their financial abilities. Of course, we also need to inform our patients fully and truthfully about all of their reasonable treatment options, which in the case of a general dentist or denturist should also include the option of referral to a qualified specialist. The principles of justice and veracity require us to develop and discuss fair and reasonable fees for each reasonable treatment alternative so that the patient can weigh his or her financial abilities against the risks and benefits of each treatment option in order to make an educated reasonable choice of care.

Unfortunately, the example patient from Case 1 opted to seek care from another clinician who did not seem to follow an effective ethical decision-making process that would likely have led the patient toward a full-mouth reconstruction, saving most of his teeth (see Table 1-1). The patient ended up having all of his teeth extracted and dentures made from a chain dental practice, being told that at a later date that implants would solve his problems. While complete exodontia may in fact have been a reasonable option for someone who was limited financially, many arguments against removing multiple teeth with sound bone structure, minimal pulpal pathology, and no dental caries in a patient with a complicated medical history would have

en overcome by the benefits of amputating teeth and replacing them with removable prostheses.

***Complete dentures are not a replacement for natural teeth; they are a substitute for no teeth.***


## Patient Selection

---

While we believe that quality complete denture therapy can be completed by any clinician who seeks, engages in, and applies adequate education to acquire the necessary skill set, we also believe that it is incumbent on every clinician to evaluate whether he or she is the most appropriate person to provide the treatment. Understanding where the line is drawn between whether you should refer to a more qualified professional or not is the hallmark of an excellent clinician. Being clear about key elements of the patient's psychosocial, medical, and dental histories are essential to our prognosis for complete denture therapy (Box 1-1). Through discussion during this first visit, it is important for you as a clinician to decide whether the patient is someone whom you will enjoy treating. Let's face it ... some people are very difficult. However, we need to remember that every clinician has a unique personality, and you may enjoy treating patients who do not necessarily interact well with another colleague with similar skills. This is why it is also important to find out what type of denture therapy has been done previously and by whom—what has been successful for your particular patient and what has not. Along those lines, why did the patient come to you? Did they respond to an advertisement; did a colleague refer them; did another patient refer them? These are important considerations because patient selection can dramatically affect the prognosis of complete denture therapy. As dentists, sometimes we think that we must treat anyone who presents to us for care; however, this is not true. Most of the time, denture patients are not critical emergency cases that we are obligated to manage.

## Managing patients' and others' expectations

When we find the patient who we would like to treat with complete denture therapy, it is essential to clarify expectations—the patient's, ours, and those who directly affect our patient's perspective (spouse, children, hypercritical friend, etc), which comes through careful and detailed



discussion with the patient. Clearly, it is essential to understand our patient's own attitude about their therapy; if he or she does not have a desire to be successful with complete dentures, the prognosis is challenged. However, we need to understand that many patients are influenced heavily by others whose opinions they value, whether correctly or incorrectly. For example, many if not all of us who have experience treating edentulous patients have provided complete denture therapy for at least one patient that ended badly with a disgruntled patient despite appropriate function, esthetics, and stability of the prostheses. Maybe the patient him- or herself initially loved the denture and even brought in cookies or donuts to thank us. However, a week later, they presented to the practice complaining that a significant other has commented, "Those teeth look fake; they don't make you look like you." Therefore, it is important that we ascertain to the best extent possible who the key influencers of our patient are so that we may attempt to involve them in the process, especially at the esthetic try-in stage, if the patient will consent to their involvement.

## Other considerations

Additional factors that can affect the success of complete denture therapy include the financial ability of the patient to pay for care, anatomical challenges, and the confidence level of the clinician to provide the complete denture therapy to that particular patient. If a patient cannot pay for or value the fees that you feel are appropriate for the level of care that you are providing, then the prognosis of care can be challenged. In fact, this goes back to patient expectations. Identification of anatomical challenges, which will be discussed in chapter 2, is critical so that an informed consent discussion can be had with the patient that clearly establishes mutual realistic expectations. Lastly, you as a clinician must be confident that you are comfortable providing care for the level of difficulty with which your patient presents. Too often, dentists attempt complete denture cases that are simply too difficult for their skill set, only to discover their limitations when the patient becomes disgruntled.

## Is There a "Right Way" to Provide Complete Denture Therapy?

We have reviewed many articles and textbooks covering complete denture therapy in addition to our own observations and experience through years of providing this therapy. Unfortunately, to date, there is no formally identified standard for providing complete denture therapy that has met the levels of moderate or severe evidence for support in the literature. However, a validated method, the Delphi method, has been used to obtain a consensus opinion to establish minimally acceptable complete denture therapy.<sup>3,4</sup> We have found that these guidelines are consistent with our experience; therefore, we endeavor to share techniques and principles in the following pages that are consistent with these guidelines with additional pearls and acceptable variations that we have found to be valuable through our practice of complete denture therapy.

## Logistical Considerations for Complete Denture Therapy

If you have decided to provide complete denture therapy, you will also need to decide if, or how much, lab work you plan to do in house and which steps in the process you will be sending to an outside dental laboratory (Table 1-2). We have found that many of the steps are more efficient and less costly to do in house with a small investment in some basic lab equipment—most of which can be purchased used through online resources—and a small laboratory space with approximately 12 square feet of counter space and a laboratory sink with appropriately wired ground fault interrupter (GFI) circuitry to accommodate approximately six 110-volt outlets. While many of the procedures during the process of providing complete denture therapy can be referred to an outside laboratory, nearly every step except for final processing can be done by trained clinical assistants within the dental office without compromising—and maybe even improving—the quality of care that you can provide. See page x at the beginning of this book for a quick reference to the list of steps and where they are discussed. The actual processing of acrylic takes space, time, and significant equipment that is commonly not available in a typical dental office to perform properly. The basic



Table 1-2 Standard sequence of complete denture therapy

CHAIRSIDE	LABORATORY
Appointment 1: Examination, imaging, and preliminary impressions	
	Custom tray fabrication
Appointment 2: Final impressions	
	Boxing and pouring
	Baseplate and wax rim fabrication
Appointment 3: Jaw records	
	Mounting models on an articulator
	Setting prosthetic teeth and preparing wax-up
Appointment 4: Esthetic try-in	
	Flasking, processing, remounting, grinding in occlusion, finishing, polishing*
Appointment 5: Delivery	
Clinical remount (may be done at delivery)	Clinical remount (may be done at delivery)
Follow-up adjustments	

Blue blocks indicate clinical appointments; green blocks indicate laboratory procedures that may be performed easily in house by trained auxiliaries.

\*This step indicates what may be most practical to refer to an outside laboratory.



FIG 1-2 A basic laboratory for in-house denture fabrication.

armamentarium that we need for a basic in-house denture laboratory includes the following (Fig 1-2):

- Stone vibrator
- Vacuum mixer and mixing bowl
- Sink with plaster trap
- Model trimmer with safety shield
- Graduated cylinder(s)
- Rubber mixing bowls and spatulas
- Laboratory knife
- Laboratory scalpel
- Dental lathe with rag wheel
- Electric handpiece
- Light box
- Flame source (Bunsen burner or butane torch)

If you do not have the facility, space, or interest to perform many of the steps of making complete dentures in house, you can still provide excellent denture therapy as long as you understand the process and can troubleshoot when challenges arise. Unfortunately, it is common for the dentist to be blamed when there is a problem with work provided by an outside laboratory. While occasionally this may in fact be the case, it is essential that you accept the





licensed professional can troubleshoot with knowledge and make corrections objectively. Just like any other procedure in healthcare, we need to be confident with the skills and knowledge of our lab technicians because ultimately, the quality of the final product and the therapy that it provides for the patient is our responsibility as the licensed clinician.

## What Happens Once You Have Decided to Provide Denture Therapy?

---

### How Do You Get Reimbursed for Denture Therapy?

---

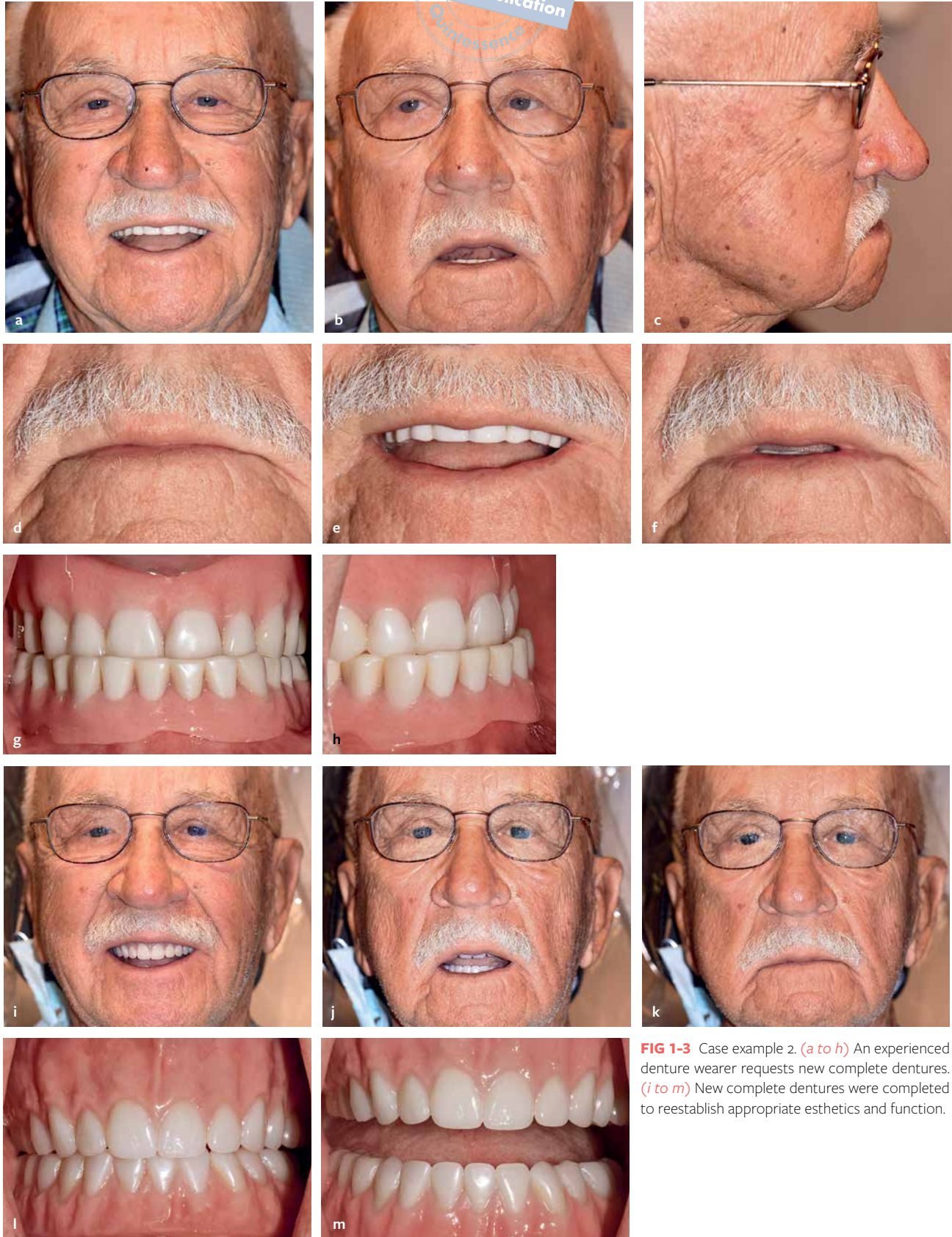There are many different ways to determine fees. For those who are contracted with third-party payers, fees may be contractually established. However, it is important that you evaluate the actual costs that it takes for you to provide complete denture therapy to determine whether or not it is fiscally reasonable to provide denture therapy for preestablished third-party fee schedules.<sup>5</sup> While our fees can generally be compared with fee survey analyses to assess where our fees fall with other surrounding providers,<sup>6</sup> we suggest that you set ethical and fair fees based on a cost analysis, including your personally desired earnings. While fee determination is outside the scope of this text, we encourage you to meet with a certified public accountant who understands dental practices to establish a break-even fee per hour, which must include your wage as a fixed expense. In general, the fee should include the laboratory fees (including applicable taxes) and associated shipping costs plus the number of anticipated clinical hours multiplied by the hourly break-even fee. Remember that your fee should also take into consideration an ethical self-assessment of the level of care that you believe you can provide based on your experience, training, and skill set. If you are not able to make the same income from providing denture therapy as you do for any other dental therapy or procedure, it will likely be difficult to enjoy providing complete denture therapy except in altruistic cases.

Let's take look at a realistic case example of a patient who presents for new complete denture therapy. A 75-year-old gentleman has worn this particular set of dentures for over 30 years. To his recollection, he has not had any problems with his denture until recently, when he started to get "a few sore spots" on his lower arch. His initial request is for a reline of his mandibular denture because one of his friends told him that a reline would fix his sore spots. Suffice it to say that you have determined that new dentures are indicated and that a reline would be woefully inadequate to address his needs appropriately (Figs 1-3a to 1-3h).

Would you feel comfortable managing this case? At this point, you may or may not recognize what makes this a challenging case. However, we will endeavor to not only make those challenges clear to you, but also to demonstrate how those challenges can be managed to provide a favorable outcome. To get you started in your thought process, let's break down this case to assess whether ethically it is appropriate to treat this case (Table 1-3) and to answer the questions that were posed earlier about the considerations for this case (Table 1-4).

Ultimately, the question for each patient that we encounter in our practices should be, "Is this a case that I would like to treat?" If so, we believe that with the appropriate experience and following many of the principles outlined in these pages, you may be able to provide excellent complete denture therapy for even challenging cases like Case 2 (Figs 1-3j to 1-3m). In fact, you might want to develop a basic screening questionnaire to use when you evaluate a complete denture therapy, such as the one shown in Fig 1-4. However, if you have challenges answering more than one or two of the questions mentioned previously (see page 4), even after mastering this text, then a referral to an appropriate prosthodontist should be considered.

Copyright  
Not for publication  
Quintessence



**FIG 1-3** Case example 2. (a to h) An experienced denture wearer requests new complete dentures. (i to m) New complete dentures were completed to reestablish appropriate esthetics and function.

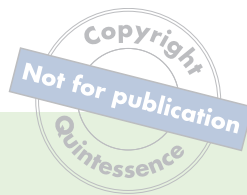

**Table 1-3 Ethical decision-making considerations for Case 2**

Autonomy	Options to be considered include (1) maxillary and mandibular relines, (2) maxillary and mandibular rebases, (3) new maxillary and mandibular complete dentures, (4) implant-supported prostheses of several types, and (5) reline or rebase of the maxillary denture and new mandibular denture.  The patient presented with misinformation about what relining only the mandibular denture would do. Informed consent involves a thorough discussion about expectations, norms, and risks of compromising optimal practice. Although implants should be discussed as an option, the patient first needs to accept the fact that new dentures are indicated.
Nonmaleficence	Providing reline therapy for prostheses that present with significant functional and esthetic compromise is not in the patient's best interest and will likely create further discomfort by changing the patient's adaptation to his existing dentures. Making a new mandibular denture against a compromised maxillary complete denture is generally unpredictable and may create further discomfort.
Benevolence	It is in the patient's best interest to provide new maxillary and mandibular denture therapy. Since any compromise to this solution is unpredictable, that is not in his best interest. Dental implant therapies, while they should be discussed as an option, should not be prematurely initiated without first establishing appropriate new complete dentures for improved prognosis.
Justice	Because this patient clearly has many functional indications for new complete denture therapy, it is just to recommend new denture therapy. Because the patient has not expressed interest in advanced implant therapy, implants should not be overly presented except in discussion as a potential option.
Veracity	Because this patient has adapted over many years to a severe compromise in esthetics, vertical dimension, and function, it is essential that he understands the adaptation to new complete dentures that will be necessary and to understand that this is a challenging case due to anatomical considerations, advanced ridge resorption, and many other variables. His attitude and open communication are essential to the prognosis of therapy.

**Table 1-4 Consideration for prognosis of Case 2**

Expectations of the patient's significant others	The patient reports that he lives alone and states that he is very independent.
Patient expectations	The patient wants to be able to chew without pain. He appears to be reasonable.
Previous complete denture history	This is his second set of dentures, and they are 30+ years old. He was completely edentulated over 50 years ago in his early 20s.
What was successful?	Two previous sets of dentures have been successful. His only difficulties have occurred in the past few months with denture sores.
What was not successful?	Nothing that the patient can recall.
Anatomical challenges	Severe ridge resorption is present on the maxillary and mandibular arches.
Patient attitude	Reasonable; he desires improved function.
Financial considerations	The patient reports a moderate financial challenge, but he can afford to finance complete denture therapy over time.



## Complete Denture Screening

Patient: \_\_\_\_\_ Date: \_\_\_\_\_

Location of complete dentures:  Maxilla  Mandible

Complaint/brief history:

Condition of dentures:  Acceptable  Unacceptable

Retention/stability:  Inadequate  Adequate  Adhesive used

Flanges:  Overextended  Inadequate  Overcontoured

Teeth:  Heavily worn  Broken  Ceramic  Resin  Occlusal instability

Occlusion relative to ridge anatomy:  Appropriate  Inappropriate

Occlusal plane:  Improper  Appropriate

VDO:  Excessive  Insufficient

Maxillary anterior tooth display:  Appropriate  Excessive  Inadequate

Implants:  None  Discussed Present in area of:

Soft tissue/oral cancer screening:  No obvious concerns  Epulis fissuratum  Concerns warranting further investigation

TMJ/muscle concerns:

Anatomical challenges:  Tori ↑↓  Soft tissue attachment  Severe ridge atrophy

Tx plan:  New CDs  Rebase  Reline  Repair  Prepros surgery  Tissue cond

Next visit:

Referrals made:

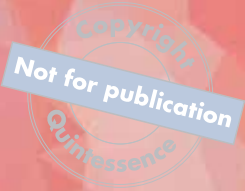Assistant: \_\_\_\_\_ Dentist: \_\_\_\_\_

**FIG 1-4** An example complete denture screening form that may be used to document basic findings of a denture examination.

## References

1. National Institute of Dental and Craniofacial Research. Tooth Loss in Seniors. <https://www.nidcr.nih.gov/research/data-statistics/tooth-loss/seniors>. Accessed 17 November 2020.
2. Huff K, Huff M, Farah C. Ethical decision-making for multiple prescription dentistry. *Gen Dent* 2008;56:538-547.
3. Linstone HA, Turoff M. *The Delphi Method: Techniques and Applications*. Boston: Addison-Wesley, 1975.
4. Owen CP. Guidelines for a minimum acceptable protocol for the construction of complete dentures. *Int J Prosthodont* 2006;19:467-474.
5. McKenzie S. 10 steps to solid fees for your dental practice. *Dentistry IQ*. <https://www.dentistryiq.com/practice-management/fees/article/16359810/10-steps-to-solid-fees-for-your-dental-practice>. Accessed 25 March 2020.
6. Doherty M. Using the fee schedule to create sustainability and affordability in the dental practice. *Dentistry IQ*. <https://www.dentistryiq.com/practice-management/fees/article/16360772/using-the-fee-schedule-to-create-sustainability-and-affordability-in-the-dental-practice>. Accessed 25 March 2020.

# Index



Page numbers followed by “t” denote tables, “f” denote figures, and “b” denote boxes.

## A

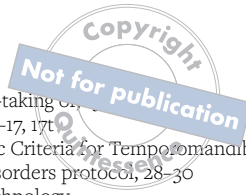
Abducens nerve, 27t  
Abutment teeth, 164–166, 173  
Accessory nerve, 27t  
Acoustic nerve, 27t  
ACP classification system. *See* American College of Prosthodontists, classification system.  
Acrylic resin denture teeth, 118  
Advocacy, for patients, 13–15  
Aging population, 1  
Air-inhibited layer, 58  
Airway  
  examination of, 37, 39  
  Mallampati score for, 37, 41f  
  oropharyngeal, 37, 39  
  sleep-related breathing disorder screenings, 36–37, 38f–39f, 40b  
  support for, 39, 41  
Ala-tragus line, 100, 113f  
Alginate impression, 42–44, 62, 174  
Alveolar bone, 31, 184  
Alveolar ridge  
  edentulous. *See* Edentulous ridges.  
  residual, cleaning of, 34  
  resorption of  
    anterior maxilla, 96  
    bite collapse caused by, 101  
    denture reevaluation in patients with, 185  
  description of, 183  
  loss of adaptation of prosthesis, 189  
  nutrition effects on, 184  
  prognosis based on, 22  
American College of Prosthodontists  
  classification systems, 30, 31t–32t  
  terminal dentition definition by, 161  
American Dental Association, 36–37, 38f–39f, 40b  
Angular cheilitis, 25  
Anterior teeth  
  maxillary, wax setup for, 128–129, 128f–129f  
  selection of, 109–111  
  shape and form of, 111  
Arbitrary facebow, 112, 114  
Armamentarium  
  for delivery appointment, 154, 154f  
  for dental laboratory, 6, 6f  
  for occlusal rim formation, 81, 81f  
Articulator  
  calibration of, 105–107  
  definition of, 113  
  facebow record for, 111–115, 113f–115f  
  fully adjustable, 113  
  mounting master cast on, 116, 116f  
  semiadjustable, 105–106, 113–114, 114f  
  setup templates for, 137f, 137–138  
  simple hinge, 113–114, 114f  
Autonomy, 3t, 9t, 162, 167, 187  
Autorotation of the mandible, 108

## B

Baseplate  
  curing of, 77, 77f  
  definition of, 68, 76  
  master cast inspection, 77–78, 77f–78f  
  materials for fabricating, 76–77, 77f  
  maxillary, 80f  
  record base of. *See* Record base.  
  relining of, 80, 80f  
  separation of, from master cast, 79  
  thermoplastic laminated, 83–84, 84f  
  visible light cured, 76, 78f  
  waxes, 81  
Benevolence, 2, 3t  
Benevolence, 3t, 9t, 163, 168, 187  
Berlin Questionnaire, 37, 39f–40f  
Bilevel positive airway pressure, 41  
BiPAP. *See* Bilevel positive airway pressure.  
Bis-acryl, 199, 201f  
Bite fork, 114  
Bite registration, 85, 106  
Blockout, 56–57, 79  
Border molding, 59–60, 60b, 60f, 60t, 76  
Box and pour technique, 70–75, 71f–75f, 75b  
Boxing wax, 42  
“Branching technique,” 64, 101  
Buccal frenum, 53  
Buccal vestibule, 52  
Buccalized occlusion, 125f, 125–126, 132, 133f  
“Burn through,” 57

## C

CAD/CAM technology  
  laboratory processing with, 147, 147f–148f  
  for record base fabrication, 84–85, 86f  
Cameo, 188b, 199  
Camper’s plane, 96, 96f  
*Candida albicans*, 33f  
Canine eminentia, 57  
Canine-guided occlusion, 122–123, 123f  
Case analysis, 9t  
Cast, master. *See* Master cast.  
CBCT. *See* Cone beam computed tomography.  
Centric occlusion, 90  
Centric relation, 28, 101, 103, 105f, 107  
Ceramic denture teeth, 118  
Chairside techniques  
  for denture duplication, 200–201  
  for relining, 180, 189  
Chewing, 11, 158  
Christensen phenomenon, 106  
Class I occlusion, 97, 98f  
Cleaning  
  at delivery appointment, 152  
  of denture, 34, 159  
  of soft tissue, 34  
Closed-mouth impression technique, 192  
Closest speaking space, 99, 99f  
Cohesion, 120–121  
Combination syndrome, 34, 34f  
Communication, 13  
Compensating curve, 121f, 121–122  
Complete denture  
  adapting to, 158  
  adjustments to, 158–159  
  caring for, 158f  
  case examples of, 2f–3f, 7, 8f, 9t  
  cleaning of, 34, 159  
  construction methods for, 113  
  decision making regarding, 2–4  
  definitive, 170, 171t  
  examination for. *See* Examination.  
  existing, evaluation of, 35–36, 185–188  
  factors that affect, 4b, 4–5  
  function of, 157–158  
  immediate, 170, 171t, 178, 179f, 181  
  inspection of, 153, 153f  
  interim, 170, 171t  
  logistical considerations for, 5–7, 6f, 6t  
  natural teeth versus, 89  
  nighttime removal of, 159, 184  
  occlusion of, 36  
  patient satisfaction with, 2  
  prescribing of, 136–137  
  printing of, 147, 147f  
  prognosis of, 4, 4b, 11, 22  
  recall examinations for, 185  
  reference points for, 90, 91t  
  reimbursement for, 7  
  rejuvenation of, 188b, 188–189, 196  
  relevancy of, 1–2  
  repairing of, 188, 194–195  
  replacement of, 159, 183  
  resistance of, 121, 185  
  retention of, 120–121, 155–156  
  screening form for, 7, 10f  
  seating of, 154–156  
  sequence of, 6t  
  smile design for, 89–90  
  stability of, 155–156, 185  
  wearing of, 159  
Complete edentulism. *See* Edentulism, complete.  
Compression molding, 141, 142f–145f  
Cone beam computed tomography, 23, 23f  
Continuous positive airway pressure, 41  
Copyplast, 84, 84f, 199  
CPAP. *See* Continuous positive airway pressure.  
Cranial nerves, 26, 27t  
Cross-arch stabilization, 132, 132f–133f  
Crosslinked polymers, 118  
Curing  
  of baseplate, 77, 77f  
  of record base, 46  
Custom trays  
  blockout, 56–57, 79  
  border molding of, 59–60, 60b, 60f, 60t  
  cross-linked dimethacrylate material for, 88  
  designing of, 55  
  fabrication of, 54–61  
  load-bearing areas, 57f  
  mandibular arch, 55



material selection for, 58–59  
 polymethyl methacrylate for, 58  
 prescribing of, 54, 65  
 pressure applied to tissues, 55–56  
 relief, 56–57  
 undercuts, 56, 78f, 85f  
 venting of, 57  
 visible light cured materials for, 58, 59f

## D

DC/TMD protocol. *See* Diagnostic Criteria for Temporomandibular Disorders protocol.  
 Definitive denture, 170, 171t  
 Delivery appointment  
   adjustments after, 156–157  
   armamentarium for, 154, 154f  
   cleaning at, 152  
   finishing at, 151–152  
   laboratory remount at, 151–153, 152f–153f  
   overview of, 151–152  
   patient instructions, 157–159  
   preparations, 154–156  
   prosthesis inspection at, 153, 153f  
   rejuvenated denture, 196  
   sanitizing at, 152  
 Delphi method, 5  
 Denar Slidematic Facebow, 114  
 Dental gypsum, 69, 69t  
 Dental history, 13  
 Dental laboratory  
   armamentarium for, 6, 6f  
   compression molding by, 141, 142f–145f  
   description of, 5–6  
   final impressions sent to, 65  
   injection molding by, 146–147  
   master casts created by, 65  
   troubleshooting of errors by, 149t  
 Dental occlusion, 89  
 Dental stone, in master casts, 68–70, 69t, 70f  
 Dentoalveolar system, 184  
 Denture  
   complete. *See* Complete denture.  
   partial, 166–167  
 Denture adhesives, 159  
 Denture base  
   colorization of, 135  
   extension of, 188  
   prosthetic gingiva, 135–136, 136f  
   stability of, 36, 185  
 Denture history, 15–17, 16t–17t  
 Denture powders, 159  
 Denture teeth  
   acrylic resin, 118  
   angulation of, 130–131, 131f  
   anterior  
     description of, 109–111  
     mandibular, 129, 130f  
     maxillary, 128–129, 128f–129f  
   ceramic, 118  
   color of, 111, 112b, 112f  
   duplicate, 198  
   gingival margin of, 199  
   material for, 119  
   outline of, 111f  
   posterior  
     description of, 119, 119f  
     wax setup for, 131, 131f  
   selection of, 116–120  
   setting of, using digital technology, 138, 138f  
   shade selection for, 112b, 112f, 116  
   shape and form of, 111  
 Denture wearers  
   experienced, 15, 16t

history-taking on  
   new, 15–17, 17f  
 Diagnostic Criteria for Temporomandibular Disorders protocol, 28–30  
 Digital technology  
   impressions using, 63–64, 64f  
   record base created using, 84–85, 85f–86f  
   setting of denture teeth using, 138, 138f  
 Disinfection  
   of denture, 194  
   disinfectants for, 73  
   of final impression, 65  
 Duplicate denture technique, 196–201, 197f–201f

## E

Earbows, 112, 113f, 115  
 Edentulism  
   complete. *See also* Terminal dentition.  
     ACP classification system for, 30, 31t  
     airway examination in, 37, 39  
     examination of, 12, 12b  
     maxilla, 30, 32t  
     prevalence of, 1  
     range of motion measurements in, 29–30  
     reference points for, 90t  
     temporomandibular joint stability  
       evaluations, 30  
       partial, 164–167  
 Edentulous ridges  
   changes in, 183–184  
   examination of, 30–32, 31t–32t  
   mandibular, 51f  
   resorption of, 50f–51f, 96, 183, 189  
 Epulis fissuratum, 33, 33f  
 Epworth Sleepiness Scale, 37, 38f, 40b  
 Esthetic evaluation, 35–36  
 Esthetic try-in, 134–137  
 Ethical decision making, 2, 3t, 4, 7, 9t, 162–163, 167–168, 186–187  
 Ethical principles, 2, 3t, 9t, 162–163, 167–168  
 Exacting patients, 18, 19t  
 Examination  
   airway. *See* Airway.  
   cone beam computed tomography, 23, 23f  
   cranial nerve screenings, 26, 27t  
   edentulism, 12, 12b  
   edentulous ridges, 30–32, 31t–32t  
   elements of, 12, 12b  
   existing prosthesis evaluation, 35–36  
   getting started, 11–12  
   history of present illness. *See* History of present illness.  
   joints, 35–36  
   muscles, 35–36  
   oral cancer screening, 24–25, 24f–25f  
   radiographic evaluation, 22–24, 23f–24f  
   soft tissue, 25–26, 26f, 33–35  
   treatment planning after, 41–42  
 Expectations, of patients, 4–5

## F

Facebow record, 111–115, 113f–115f, 177  
 Facial muscle tone, 25  
 Facial nerve, 26, 27t  
 Facial shape, 111, 111f  
 Facially generated smile design  
   definition of, 91–93  
   illustration of, 110f  
   occlusal plane for, 98, 99t  
 Facially generated treatment planning, 91  
 Fees, 7

Final impression  
   alginate, 42–44, 62, 174  
   anatomical landmarks for, 49, 50f, 51–53  
   border molding in, 59–60, 60b, 60f, 60t  
   criteria for selecting, 49  
   custom trays for. *See* Custom trays.  
   definition of, 49  
   digital, 63–64, 64f  
   disinfecting of, 65  
   functional, 64  
   hybrid technique for, 64, 64f  
   mandibular landmarks of, 52–53  
   master cast fabrication from, 67  
   material for, 54  
   maxillary landmarks of, 51–52, 54f  
   mucostatic, 61–63, 62f  
   polyether materials for, 61  
   prescribing of, 54, 65  
   requirements for, 49  
   selective pressure, 54, 61  
   single-entry approach, 62–63  
   stock trays in, 62–63  
   technique for, 53–54  
 Finishing, of occlusal rim, 82–83  
 Flasking, 198, 200  
 Flat-plane occlusion, 123, 123f  
 Fox plane, 96, 97f  
 Fraud, 13t  
 Freeway space, 101  
 Frontal view, 92f–93f, 92–93  
 Full-mouth radiographic series, 24  
 Fully adjustable articulators, 113  
 Fully balanced occlusion, 121–122, 122f  
 Fully seated condylar position, 28  
 Functional impressions, 64, 191–192

## G

GAD-7, 19, 19f  
 Genioglossus muscle, 53  
 Gingiva, prosthetic, 135–136, 136f  
 Glossopharyngeal nerve, 26, 27t  
 Graduated cylinder, 69, 70f  
 Gross negligence, 13t

## H

Hamular notch area, 51–52, 56–57  
 History of present illness  
   conversational approach to, 12–13  
   dental history, 13  
   denture history, 15–17, 16t–17t  
   medical history, 12  
   psychologic considerations, 17–21  
   situations requiring legal action, 13, 13t  
   terminal dentition patients, 17, 18t  
 Hopeless dentition, 17, 18t  
 Human papillomavirus-16, 24, 24f  
 Human trafficking, 13t  
 Humidor, 43–44  
 Hybrid occlusion, 126, 126f  
 Hypercritical patients, 18, 19t  
 Hypoglossal nerve, 26, 27t  
 Hysterical patients, 18–19, 19t

## I

Immediate denture, 170, 171t, 178, 179  
 Impression  
   digital, 63–64, 64f  
   disinfecting of, 65  
   final. *See* Final impression.  
   functional, 191–192  
   indirect, 190f, 190–191

laboratory process for, 192–1923  
 mucostatic, 61–63, 62f  
 preliminary, 42–45, 54  
 soft tissue health effects on, 33  
 walking, 191

Impression technique  
 alternative, 44–45  
 closed-mouth, 192  
 criteria for selecting, 49  
 requirements for, 49  
 selection of, 174–176, 175f–176f  
 static, 192  
 for terminal dentition, 174–176, 175f–176f

Indirect impressions, 190f, 190–191

Inferior alveolar nerve, 24

Informed consent, 21–22, 173–174, 179

Injection molding, 146–147

Intaglio, 188b, 189

Interdisciplinary communication, 172

Interim denture, 170, 171t, 181

Intraoral scanning, 63, 64f

Irreversible hydrocolloid impression, 62, 174

## J

Jaw records  
 description of, 94  
 lip support, 95–101  
 neutral zone, 94, 95f  
 occlusal plane, 95–101  
 terminal dentition, 176–177  
 treatment position, 103–108  
 vertical dimension of occlusion, 101–103

Joints, 35–36

Justice, 3t, 4, 9t, 163, 168–169, 187

## K

Kinematic facebow, 112

## L

Labial frenum, 52

Labial vestibule, 52–53

Laboratory. *See* Dental laboratory.

Laboratory remount, 151–153, 152f–153f

Lang Denture Duplicator, 196, 197f

Lateral pterygoid muscle, 28–29

Layered impression technique, 175f

Lingual frenum, 53

Lingualized occlusion, 123–125, 124f, 132, 132f, 188

Lip support, 82f, 83, 95–101

## M

Mallampati score, 37, 41f

Malocclusion, skeletal, 103

Mandible  
 autorotation of, 108  
 border molding, 60b  
 edentulous ridge resorption in, 51f  
 final impression landmarks, 52–53  
 master cast of, 75b  
 muscle attachments on, 32t  
 preliminary impression of, 43b

Mandibular advancement splint, 41

Mandibular anterior teeth, 128f–130f, 128–129

Mandibular arch, 166

Mandibular condyle, 28, 30

Mandibular occlusal plane, 36

Masseter muscle, 28

Masseteric groove, 52

Master cast  
 art form of, 68, 70, 74, 74f  
 baseplate separation from, 79  
 border areas of, 78  
 box and pour technique for, 70–75, 71f–75f, 75b  
 critical areas of, 68, 68f  
 elements of, 68  
 fabrication of, 67–68, 67f–68f  
 frame of, 72, 72f–73f  
 inspecting of, 77–78, 77f–78f  
 mandibular, 75b  
 maxillary, 75b  
 mounting of, 116, 116f, 142f  
 pouring of, 72f, 72–73  
 prescription for, 65  
 remount keys, 74, 75f  
 remounting of, 153f, 156  
 separating of, 73  
 stone used in, 68–70, 69t, 70f, 116f  
 trimming of, 73–74, 74f

Masticatory mucosa, 185

Masticatory muscles, 28–30

Maxilla  
 baseplate, 80f  
 border molding, 60b  
 edentulous, 30, 32t  
 final impression landmarks, 51–52, 54f  
 hamular notch area of, 51–52  
 master cast of, 75b  
 occlusal plane, 97–99, 97f–99f  
 occlusal rim, 80, 81  
 preliminary impression of, 42b–43b  
 tongue's role in growth and development of, 39  
 U-shaped, 50f  
 V-shaped, 50f, 166f

Maxillary occlusal plane, 92

Maxillary record base, 115f

Maxillary teeth  
 anterior, 128–129, 128f–129f  
 positioning of, in smile design, 91–93, 92f

Maxillomandibular relationship, 30, 33t

Maximum intercuspation, 36

Medial pterygoid muscle, 28

Medical history, 12

Methyl methacrylate, 185

Microstone, 69

Ministar S, 83, 84f

Modified lingualized occlusion, 125, 125f

Mounting, of master cast, 116, 116f

Mounting plaster, 68

Mucostatic impression, 61–63, 62f

Muscles, 35–36

*Mycobacterium tuberculosis*, 65

## N

Negative space, 126, 126f

Neutral zone, 94, 95f

Nonmaleficence, 3t, 9t, 162–163, 167–168, 187

## O

Obstructive sleep apnea, 37, 41

Occlusal adjustments, 156f

Occlusal plane, 95–101  
 mandibular, 102t  
 maxillary, 97–99, 97f–99f

Occlusal rim  
 adjustments to, 100–101  
 as anterior bearing point, 177  
 customization of, 90  
 finishing of, 82–83

formation/fabrication of, 81–82, 85, 81f–82f, 176

functional elements with, 98

incisal platforms of, 100

maxillary, 80–81, 95, 98  
 polishing of, 82–83  
 wax, 80–81

Occlusal scheme, 120–126, 121f–126f

Occlusion  
 buccalized, 125f, 125–126, 132, 133f  
 canine-guided, 122–123, 123f  
 centric, 90  
 dental, 89  
 flat-plane, 123, 123f  
 fully balanced, 121–122, 122f  
 hybrid, 126, 126f  
 lingualized, 123–125, 124f, 132, 132f, 188  
 maxillary plane of, 188b  
 modified lingualized, 125, 125f  
 vertical dimension of, 36, 51, 80, 101–104, 151, 156, 165, 188b, 190f

Oculomotor nerve, 27t

Olfactory function, 26

Olfactory nerve, 27t

Optic nerve, 27t

Oral cancer screening, 24–25, 24f–25f, 185

Oral surgery, preprosthetic, 169, 171–173, 178

Oropharyngeal airway, 37, 39

Osteoclasts, 183–184

## P

Palatal vault, 95

Palate, 39

Panoramic radiographs, 22, 23f

Parotid gland, 26

Partial denture, 166–167

Patient(s)  
 advocacy for, 13–15  
 attitude of, 4t  
 communication with, 13, 178–180  
 esthetic evaluation of, 35–36  
 esthetic try-in with, 134–137  
 expectations of, 4–5, 157, 178–180  
 with hopeless dentition, 17, 18t  
 instructions at delivery appointment, 157–159  
 mental types of, 18–19  
 psychologic considerations for, 17–21  
 screening form for, 7, 10f  
 selection of, 4–5, 7

Phased treatment approach, 181

Philosophical patients, 18, 19t

PIP. *See* Pressure-indicating paste.

Play-Doh, 71f, 71–73, 156

Pleasure compensation curve, 120

PMMA. *See* Polymethyl methacrylate.

Polishing, of occlusal rim, 82–83

Polyether materials  
 for border molding, 59  
 for final impression, 61  
 single-entry technique use of, 63  
 stability of, 65

Polymethyl methacrylate, 58, 191, 199

Polysiloxane impression materials, 73

Postdam, 52, 95

Posterior denture teeth, 119, 119f

Posterior palatal seal, 95, 96f

Posterior teeth  
 description of, 119, 119f  
 wax setup for, 131, 131f

Pound Triangle, 101, 101f

Pouring, of master cast, 72f, 72–73

Preliminary impression, 42–45, 54

Preprosthetic oral surgery, 169, 171–173, 178

Pressure-indicating paste, 154, 155f  
 Profile view, 92, 92f  
 Prognosis, 4, 4b, 11, 22  
 Proprioception, 164  
 Protrusive bite registration, 106, 106f  
 Pseudo-Class III scenario, 107, 108f  
 Psychologic considerations, 17–21  
 Pterygomandibular ligament, 52

## Q

Questionnaires  
 history-taking, 12  
 temporomandibular joint pain or disorder,  
 12, 28, 29f

## R

Radiographic evaluation, 22–24, 23f–24f  
 Rebase/rebasing  
 definition of, 188b  
 impressions for, 64, 189–192  
 indications for, 189  
 resilient liner, 193–194  
 tooth replacement at, 186  
 Recall evaluations, 159  
 Record base  
 applying the material, 78–79  
 CAD/CAM fabrication of, 84–85, 86f  
 complete. *See* Baseplate; Occlusal rim.  
 curing of, 46  
 definition of, 76  
 digital, 84–85, 85f–86f  
 finishing of, 79–80  
 fitting of, 94–95, 95f  
 function of, 76, 82–83  
 lip support evaluations using, 82f, 83, 95–101  
 maxillary, 115f  
 occlusal rim added to. *See* Occlusal rim.  
 relining of, 94  
 in terminal dentition, 176  
 visible light cured, 79f  
 Rejuvenation, of denture, 188b, 188–189, 196  
 Relief, 56–57  
 Reline jig, 192–193, 193f  
 Relining  
 baseplate, 80, 80f  
 branching technique for, 64  
 chairside technique for, 180, 189  
 definition of, 188t  
 definitive complete denture, 170  
 illustration of, 189f  
 of immediate denture, 180  
 impression making for, 189–192  
 indications for, 189f, 189–190  
 Remount keys, 74, 75f  
 Remounting, 153f, 156  
 Removable partial denture, 166–167  
 Repair, 188t, 194–195  
 Resilient liner, 193–194  
 Resistance, 121, 185  
 Resting tongue position, 25  
 Retention, 120–121, 155–156  
 Retrodiscal tissue, 28  
 Risks, 21–22  
 Root tips, 22

## S

Salivary flow rate, 26  
 Salivary glands, 26  
 Screening  
 complete denture, 7, 10f  
 cranial nerve function, 26, 27f

oral cancer, 24–25  
 temporomandibular joint pain or disorder  
 Sectional impression technique, 175f  
 Selective pressure impressions, 54, 61  
 Semiadjustable articulator, 105–106, 113–114, 114f  
 Setup template, 137f, 137–138  
 Simple hinge articulator, 113–114, 114f  
 Skeletal malocclusion, 103  
 Sleep-related breathing disorders, 36–37,  
 38f–39f, 40b  
 Smile design  
 anterior teeth in, 89  
 dentures, 89–90, 110  
 facially generated, 91–93, 98, 99t  
 frontal view, 92f–93f, 92–93  
 incisor length in, 90  
 maxillary teeth positioning in, 91–93, 92f  
 natural teeth, 89–90  
 posterior teeth in, 89  
 profile view, 92, 92f  
 systematic approach to, 94f  
 Smile evaluations, 174, 174f  
 Soft tissue  
 cleaning of, 34  
 conditioning of, 34–35  
 digital impressions affected by health of, 63  
 examination of, 25–26, 26f  
 health of, 33–35, 49  
 trauma to, 25  
 Sphenoid bone, 51  
 Squamous cell carcinoma, 24f, 26  
 SRDB. *See* Sleep-related breathing disorders.  
 Static impression technique, 192  
 Stensen duct, 26  
 Stock trays, 62–63  
 Stomatognathic system, 28  
 Stone cast, 63–64, 68–70, 69t, 70f, 116f  
 STOP-BANG Questionnaire, 37, 38f, 40b  
 Sublingual gland, 26  
 Submandibular gland, 26  
 Surfactants, 73  
 Surgical guide, 172, 172f

## T

Teeth. *See* Anterior teeth; Denture teeth;  
 Posterior teeth; Terminal dentition.  
 Temporalis muscle, 29  
 Temporomandibular disorders, 30  
 Temporomandibular joint  
 description of, 28  
 Diagnostic Criteria for Temporomandibular  
 Disorders protocol, 28–30  
 palpation of, 28  
 questionnaire about pain or disorder in, 12,  
 28, 29f  
 Terminal dentition. *See also* Edentulism.  
 as abutment teeth, 164  
 definition of, 161  
 dental laboratory steps for, 176–177  
 description of, 17, 18t  
 diagnosis of, 161–164  
 health considerations in, 167–170  
 impression technique for, 174–176, 175f–176f  
 jaw records, 176–177  
 patient acceptance of, 161  
 patient communication and expectations  
 about, 178–180  
 physical injury as cause of, 165  
 prosthesis construction for, 173–181  
 tooth position considerations for, 176  
 treatment scenarios for, 164–167, 165f  
 vertical dimension of occlusion, 165  
 Thermoplastic laminated baseplate, 83–84, 84f

Thermoplastic surgical guide, 172f  
 Tissue conditioner/conditioning, 180–181, 191f  
 Titanium dioxide, 85, 85f  
 Tongue  
 in airway function, 37  
 in impression taking, 53  
 lingual frenum of, 53  
 resting position of, 25, 158  
 Torus palatinus, 169, 169f, 172f, 172–173  
 Treatment planning/treatment plans  
 after examination, 41b, 41–42  
 facially generated, 91  
 phased approach, 181  
 in terminal dentition, 173–174  
 Triad Denture Base, 76  
 Triad Model Release Agent, 78  
 Trial base, 68, 76  
 Trigeminal nerve, 26, 27t  
 Trigger points, 29  
 Trimming, of master cast, 73–74, 74f  
 Trochlear nerve, 27t  
 Trubyte indicator, 110, 110f  
 Try-in, esthetic, 134–137

## U

Undercuts, 56, 78f, 85f, 154, 154f

## V

Vagus nerve, 27t  
 Vanity denture, 196–201, 197f–201f  
 VDO. *See* Vertical dimension of occlusion.  
 VDR. *See* Vertical dimension at rest.  
 Venting, of custom trays, 57  
 Veracity, 3t, 9t, 163, 169, 187  
 Vertical dimension at rest, 102  
 Vertical dimension of occlusion, 36, 51, 80,  
 101–104, 151, 156, 165, 188b, 190f  
 Vestibulocochlear nerve, 27t  
 Vibrating line, 52  
 Vinyl polysiloxane  
 bite registration, 114  
 border molding using, 59, 60f  
 duplication denture technique using,  
 196–198, 198f  
 mucostatic impressions using, 61, 62f  
 single-entry technique use of, 63  
 stability of, 65  
 tissue stops created with, 190, 191f  
 Visible light cured materials  
 baseplate fabrication from, 76, 78f  
 custom trays fabrication from, 58, 59f  
 Vita classical A1–D4 shade guide, 116  
 Vitamin D<sub>3</sub>, 184

## W

Walking impression, 191  
 “Wall cleaner compound,” 71  
 Water-to-powder ratio effect, 69, 72  
 Wax rim. *See* Occlusal rim.  
 Wax setup  
 angulation, 130–131, 131f  
 description of, 126–128  
 mandibular anterior teeth, 129, 130f  
 maxillary anterior teeth, 128–129, 128f–129f  
 Wax-up  
 checking of, 134, 134f  
 compression molding, 141, 142f–145f  
 esthetic try-in, 134–137  
 Wharton duct, 26