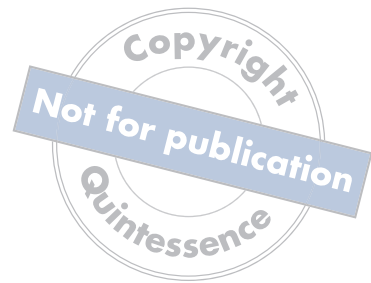

ITI

Treatment Guide

Editors:

D. Buser, U. Belser, D. Wismeijer





ITI

Preface

Treatment Guide

In the past 15 years, the use of osseointegrated implants has become the standard of care for the rehabilitation of fully and partially edentulous patients, leading to a rapid expansion of implant therapy in dental offices.

This positive development was supported by several factors and trends. Firstly, implant therapy is meeting with much greater acceptance—not only by patients, but also by dentists. The excellent documentation of osseointegrated implants in prospective clinical studies (with up to ten years of follow-up) and good clinical results have both contributed to this increased acceptance. Secondly, the prosthodontic aspect of implant therapy has been simplified by precise prefabricated components, so general practitioners can easily treat patients with implant-supported restorations. Thirdly, there has been significant progress in bone-augmentation procedures (techniques to overcome local bone deficiencies such as guided bone regeneration or sinus grafting). These surgical procedures are routinely used for implant patients today; they have broadened the indications for oral implant therapy, particularly in partially edentulous patients.

As a result, the single-tooth replacement has become the most common indication for implant therapy in recent years. Parallel to this, “novel techniques,” such as immediate implants (with or without flap elevation) and immediate loading, have been promoted to make implant therapy more patient-friendly. Most of these new techniques, however, have not yet been sufficiently documented clinically. Carefully designed, randomized, controlled clinical studies are required to evaluate their value for daily practice.

With this rapid expansion of implant therapy, involving more than 100,000 clinicians worldwide, quality control in implant dentistry has become an increasing challenge. Universities and scientific associations have been asked to make efforts to assure that the implant therapy provided is of high quality in order to maintain the good reputation of dental implants.

The International Team of Implantology (ITI) has responded by establishing the ITI Education Committee. The main objectives of this committee are to discuss and define the



standards of care in the surgical and prosthetic aspects of implant dentistry, to integrate these standards into high-quality continuing-education courses, and to coordinate the worldwide educational efforts. Over the past eight years, the ITI has significantly increased its efforts in the area of implant education, including the establishment of the ITI Scholarship Program, which offers stipends to young clinicians and financial support for Centers of Implant Dentistry in the U.S., Europe, and Japan. In addition, the ITI organized its third ITI Consensus Conference in 2003 to discuss clinical topics of interest to implant dentistry. The proceedings were published in a special supplement of JOMI (Proceedings of the Third ITI Consensus Conference 2004).

The ITI Education Committee has decided to use these consensus proceedings to establish an ITI Treatment Guide. This guide will offer detailed clinical guidelines for specific problems in implant dentistry. The first volumes will discuss the following topics: (i) esthetic implant dentistry; (ii) loading protocols in implant dentistry; and (iii) implant placement in extraction sockets.

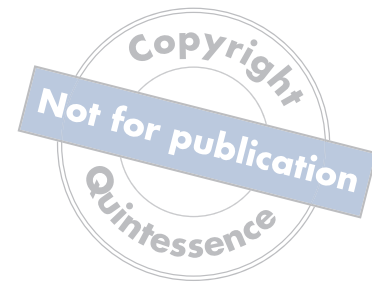These topics will be comprehensively presented with detailed recommendations for step-by-step procedures. Each treatment option will be discussed objectively, taking into account the following parameters:

- 1 Scientific documentation of the procedure through clinical studies
- 1 Objective benefits for the patient
- 1 Risks involved with the procedure
- 1 Level of treatment complexity according to the SAC (simple—advanced—complex) classification
- 1 Cost-effectiveness of the procedure

The first volume of the ITI Treatment Guide is devoted to single-tooth replacements in the esthetic zone, a topic of great interest within implant dentistry. It should be of great help to the clinician dealing with esthetic indications in implant patients.

Daniel Buser Urs C. Belser Daniel Wismeijer

Handwritten signatures of the three authors: Daniel Buser, Urs C. Belser, and Daniel Wismeijer.



Editors and Authors

Editors:

Urs C. Belser, DMD, Professor
University of Geneva
Department of Prosthodontics
School of Dental Medicine
Rue Barthélemy-Menn 19, 1211 Genève 4, Switzerland
E-mail: urs.belser@medecine.unige.ch

Daniel Buser, DMD, Professor
University of Berne
Department of Oral Surgery and Stomatology
School of Dental Medicine
Freiburgstrasse 7, 3010 Bern, Switzerland
E-mail: daniel.buser@zmk.unibe.ch

Daniel Wismeijer, DMD, Professor
Academic Center for Dentistry Amsterdam (ACTA)
Free University
Department of Oral Function
Section of Implantology and Prosthetic Dentistry
Louwesweg 1, 1066 EA Amsterdam, Netherlands
E-mail: dwismeijer@acta.nl

Authors:

Christoph Hämmerle, DMD, Professor
University of Zurich, Center for Dental and
Oral Medicine, Clinic for Fixed and
Removable Prosthodontics
Plattenstrasse 11, 8032 Zürich, Switzerland
E-mail: hammerle@zmk.unizh.ch

Ronald Jung, DMD
University of Zurich, Center for Dental and
Oral Medicine, Clinic for Fixed and
Removable Prosthodontics
Plattenstrasse 11, 8032 Zürich, Switzerland
Email: jung@zmk.unizh.ch

William C. Martin, DMD, MS
University of Florida, Gainesville
Center for Implant Dentistry
Department of Oral and Maxillofacial Surgery
1600 W Archer Road, D7-6, Gainesville, FL 32610, USA
E-mail: wmartin@dental.ufl.edu

Dean Morton, BDS, MS
University of Florida, Gainesville
Center for Implant Dentistry
Department of Oral and Maxillofacial Surgery
1600 W Archer Road, D7-6, Gainesville, FL 32610, USA
E-mail: dmorton@dental.ufl.edu

Bruno Schmid, DMD
Bayweg 3, 3123 Belp, Switzerland
E-mail: brunoschmid@vtxmail.ch

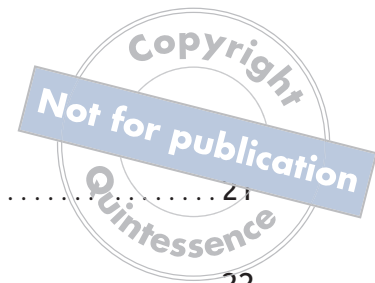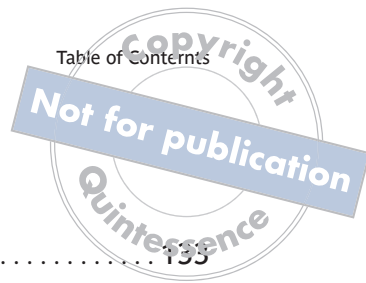


Table of Contents

1	Introduction	1
	<i>D. Buser, U. C. Belser, D. Wismeijer</i>	
2	Proceedings of the Third ITI Consensus Conference: Esthetics in Implant Dentistry	3
2.1	Consensus Statements and Recommended Clinical Procedures Regarding Esthetics in Implant Dentistry	5
2.1.1	Statements A: Long-Term Results	5
2.1.2	Statements B: Surgical Considerations	6
2.1.3	Statements C: Prosthodontic and Restorative Procedures	7
3	Pre-Operative Analysis and Prosthetic Treatment Planning in Esthetic Implant Dentistry	9
3.1	Diagnostic Factors for Esthetic Risk Assessment	11
	<i>W. C. Martin, D. Morton, D. Buser</i>	
3.1. 1	The Patient's Treatment Expectations	11
3.1. 2	Patient's Smoking Habits	12
3.1. 3	Height of the Lip Line on Smiling	12
3.1. 4	Gingival Biotype in the Treatment Area	13
3.1. 5	Shape of Missing and Surrounding Teeth	15
3.1. 6	Infection at the Implant Site and Bone Level at Adjacent Teeth	15
3.1. 7	Restorative Status of Teeth Adjacent to the Edentulous Space	16
3.1. 8	Character of the Edentulous Space	17
3.1. 9	Width of the Hard and Soft Tissues in the Edentulous Space	18
3.1.10	Height of the Hard and Soft Tissues in the Edentulous Space	19
3.1.11	Esthetic Risk Profile: Summary	19



3.2	Treatment Planning	21
	<i>W. C. Martin, D. Morton, D. Buser</i>	
3.3	Interim Restorations	22
	<i>W. C. Martin, D. Morton, D. Buser</i>	
3.4	Conclusions	24
	<i>W. C. Martin, D. Morton, D. Buser</i>	
4	Achieving Optimal Esthetic Results	25
4.1	Surgical Considerations with Regard to Single-Tooth Replacements in the Esthetic Zone: Standard Procedure in Sites without Bone Deficiencies	26
	<i>D. Buser, W.C. Martin, U. C. Belser</i>	
4.1.1.	Mesiodistal Dimension	30
4.1.2	Orofacial Dimension	31
4.1.3	Coronoapical Dimension	32
4.2	Prosthetic Management of Implants in the Esthetic Zone: General Principles and Scientific Documentation	38
	<i>C. Hämmerle, R. Jung</i>	
4.3	Decision Trees: Prosthetic Options	47
	<i>U. C. Belser</i>	
4.3.1	Regular Neck Implants	47
4.3.2	Narrow Neck Implants	48
4.4	Replacement of an Upper Right Central Incisor with a Regular Neck Implant, Restored with an All-Ceramic Crown, Transocclusally Screw-Retained	49
	<i>R. Jung</i>	
4.5	Replacement of an Upper Right Central Incisor with a Regular Neck Implant, Restored with (1) an All-Ceramic Crown, Transocclusally Screw-Retained, and (2) an Auro-Galvano Crown, Cemented, Seated on CAD/CAM Custom Mesostructures (ZrO ₂ and Titanium)	58
	<i>U. C. Belser</i>	
4.6	Replacement of an Upper Right Central Incisor with a Regular Neck Implant, Restored with an All-Ceramic Crown, Cemented	78
	<i>R. Jung</i>	
4.7	Replacement of an Upper Right Central Incisor with a Regular Neck Implant, Restored with an All-Ceramic Crown, Cemented	94
	<i>W. C. Martin</i>	
4.8	Replacement of an Upper Left Central Incisor with a Regular Neck Implant, Restored with a Ceramo-Metal Crown, Transocclusally Screw-Retained	112
	<i>R. Jung</i>	



4.9	Replacement of an Upper Left Central Incisor with a Regular Neck Implant, Restored with a Ceramo-Metal Crown, Transocclusally Screw-Retained	133
	<i>U. C. Belser</i>	
4.10	Replacement of an Upper Right Central Incisor with a Regular Neck Implant, Restored with a Ceramo-Metal Crown, Transocclusally Screw-Retained	148
	<i>W. C. Martin</i>	
4.11	Replacement of an Upper Left Persisting Deciduous Canine with a Regular Neck Implant, Restored with a Ceramo-Metal Crown, Horizontally Screw-Retained	159
	<i>U. C. Belser</i>	
4.12	Replacement of a Congenitally Missing Upper Left Lateral Incisor with a Narrow Neck Implant, Restored with a Ceramo-Metal Crown, Transocclusally Screw-Retained	178
	<i>B. Schmid</i>	
4.13	Replacement of Congenitally Missing Upper Lateral Incisors with Narrow Neck Implants, Restored with Ceramo-Metal Crowns, Cemented	187
	<i>W. C. Martin</i>	
4.14	Replacement of an Upper Right Lateral Incisor with a Narrow Neck Implant, Restored with a Ceramo-Metal Crown, Cemented	214
	<i>W. C. Martin</i>	
5	Esthetic Complications and Their Causes	231
5.1	Introduction	232
	<i>D. Buser, W. C. Martin</i>	
5.2	Case Reports	233
	<i>D. Buser, W. C. Martin</i>	
5.2.1	Patient No. 1	233
5.2.2	Patient No. 2	235
5.2.3	Patient No. 3	236
5.2.4	Patient No. 4	238
5.2.5	Patient No. 5	239
5.2.6	Patient No. 6	241
5.2.7	Patient No. 7	244
5.3	Conclusions	245
	<i>D. Buser, W. C. Martin</i>	
6	Synopsis	247
	<i>U. C. Belser</i>	
7	Literature/References	249

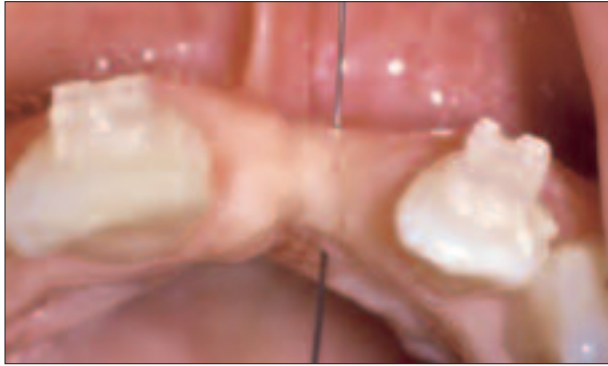
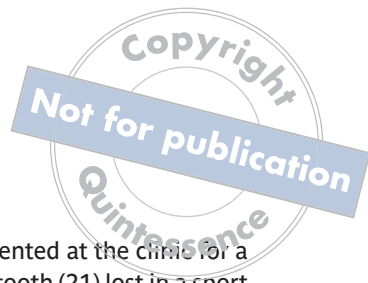

Fig 9 An attempt to "sound" for osseous support revealed a deficiency in vertical and horizontal bone

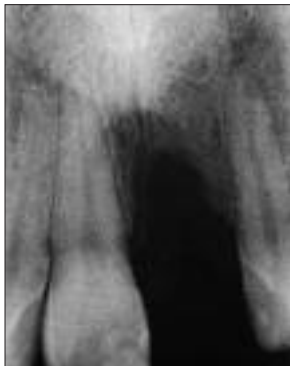

Fig 10 Periapical radiograph confirming bone deficiencies at the proposed implant site and interproximal support on the adjacent roots.

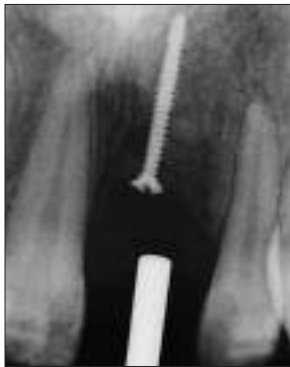

Fig 11 Periapical radiograph with the radiographic template in place.

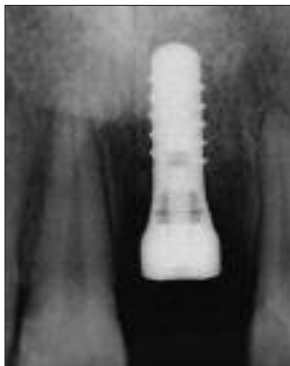

Fig 12 Postoperative radiograph depicting the placement of the implant in the coronoapical danger zone.

5.2.3 Patient No. 3

A 30-year-old female patient presented at the clinic for a consultation to replace a missing tooth (21) lost in a sport accident. Examination of the esthetic risk for her treatment revealed a medium lip line at full smile, exposing three-quarters of the clinical crowns and the tips of the papillae. The gingival biotype was thin, with highly scalloped papillae, tapered clinical crowns, and a thin band of keratinized tissue. The site analysis showed a deficiency in osseous width and height extending apically of the middle third of the adjacent roots (Fig 9).

The periapical radiograph confirmed this bone loss while showing that adequate bone support existed on the interproximal of the adjacent teeth 11 and 22 (Fig 10).

Based upon the clinical findings, the patient was informed of the high risk of esthetic failure with dental implant therapy. A plan was presented to address the hard-tissue and soft-tissue deficiencies prior to implant placement. Six months after the grafting procedure, a clinical examination revealed successful horizontal bone regeneration, while a deficiency in vertical height remained. The patient declined further tissue-enhancement procedures and desired to proceed with implant placement. A radiographic template was fabricated and a periapical radiograph taken (Fig 11).

The dental implant was placed within the orofacial and mesiodistal comfort zones, while entering the coronoapical danger zone (Fig 12).

Six weeks later, the implant was restored with a provisional restoration; the clinical result highlighted the apical position of the soft-tissue margin at site 21 related to the adjacent teeth (Fig 13).

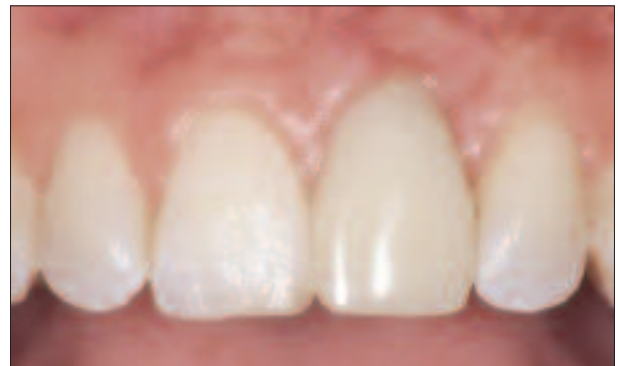

Fig 13 Provisional restoration at site 21 highlighting the apical position of the soft-tissue margin related to the adjacent teeth.

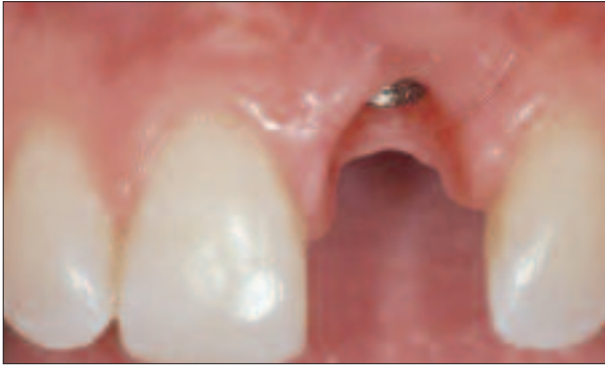

Fig 14 Clinical view of implant 21 highlighting the apical position of the soft-tissue margin relative to the adjacent teeth. The interproximal tissue support was promising.

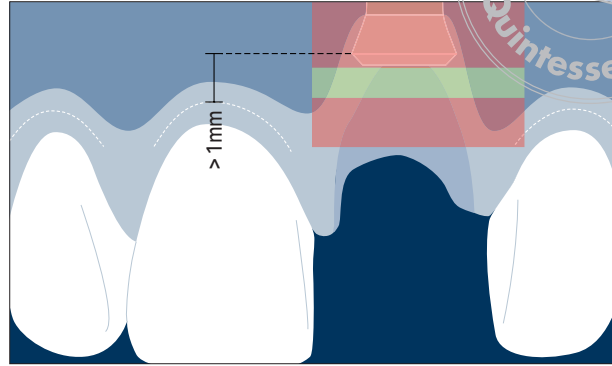


Fig 15 Implant shoulder located in the apical danger zone, with the soft-tissue margin in an apical position.

Upon maturation of the transition zone, there was interproximal tissue support, but a mucosal deficiency on the facial aspect was evident (Fig 14).

The implant shoulder was located in the apical danger zone (Fig 15). To compensate for this situation, pink ceramic material was integrated into the implant-supported superstructure. In this way, a pleasing esthetic treatment outcome could be achieved despite the compromised clinical situation (Fig 16).

The esthetic result was acceptable to the patient (Fig 17).

The postoperative periapical radiograph highlights the final position of the supporting structures (Fig 18).

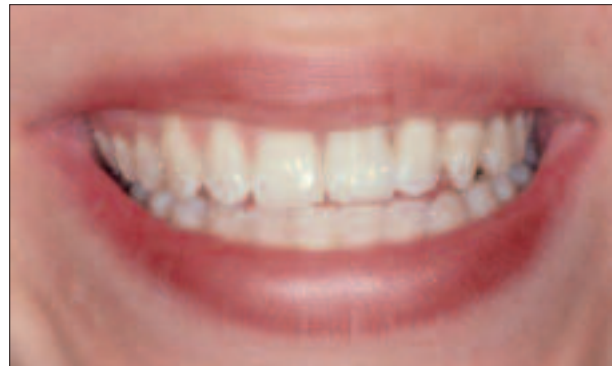

Fig 16 At full smile, the facial tissue deficiency was not visible.

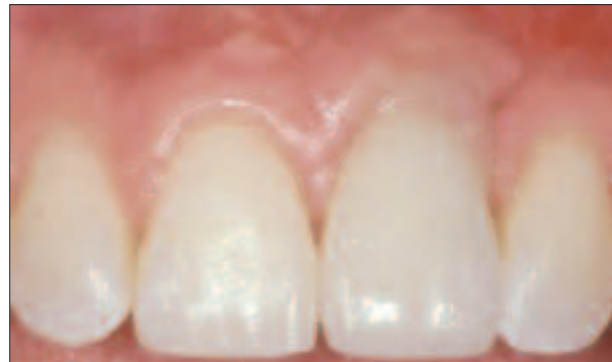

Fig 17 Pink ceramic material helped create the illusion of a harmonious soft-tissue contour.

Case summary:

This clinical case is an example of an esthetic compromise associated with clinician and patient causes and anatomical limitations. The challenges in this treatment were associated with several factors: patient limitations—time constraints and finances; surgical challenges—extensive grafting procedures with multiple procedure limits; and anatomic limitations—thin biotype coupled with severe localized atrophy. Proper esthetic risk assessment, patient education, treatment planning, and technician expertise allowed a pleasing esthetic treatment outcome, since the necessary compromises were taken into consideration before the treatment began.

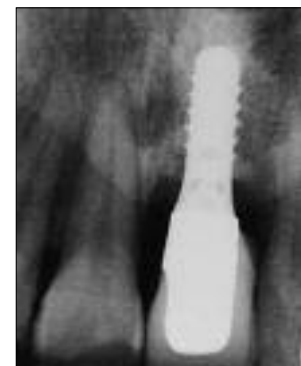

Fig 18 Periapical radiograph after insertion highlighting the final positions of the dental implant and surrounding hard tissues.