

ENRIQUE M. MERINO

# Endodontic Microsurgery

Quintessence Publishing Co. Ltd.  
London, Berlin, Chicago, Paris, Milan, Barcelona, Istanbul,  
São Paulo, Tokyo, New Delhi, Moscow, Prague, Warsaw





# Foreword

I was honored to be asked to write the foreword to Dr Enrique Merino's textbook, *Endodontic Microsurgery*. To my knowledge, it is the first comprehensive book on the subject, and this is certainly the right moment for publication. In short, this book gives the reader the current definitions of the surgical procedures that must be carried out to address endodontic problems and failures.

Although surgery has been used for centuries to solve endodontic problems and maintain teeth in the dental arch, the biological concepts, the technical procedures and the armamentarium have drastically evolved in the last 20 years. For example, apical surgery has long been performed by oral surgeons, with sometimes poor outcomes owing to lack of knowledge of the endodontic biological principles. Today, apical surgery must be regarded as an integral part of the endodontic field and a predictable treatment modality, owing to the introduction of new technological advancements coupled with refinements in soft and hard tissue management. Magnification through the use of the operating microscope, dedicated ultrasonic tips, new biomaterials for root-end filling, and guided bone regeneration have changed the outcome of surgical endodontics, which is now expected to be similar to orthograde treatment.

I have known Dr Merino for many years and I can bear witness to his passion for endodontics and periodontics. He was trained in both fields in renowned graduate programs and has lectured extensively

in his country and internationally. He is a sophisticated clinician with sound academic knowledge, as attests the exhaustive and up-to-date references available at the end of each chapter. On the other hand, the format of the book is of a high standard, well organized and easy for any clinician to read, whether a general practitioner or a specialist. The text is concise, with the addition of step-by-step procedures, clinical tips and the dedicated instrumentation used. The procedures are well described, with clear graphics and high-quality clinical illustrations. Finally, the content is comprehensive, involving all areas of microsurgery, including chapters on endo-perio relationships, treatment of bone defects and implantology.

Dr Merino must be congratulated for the enormous time spent in the preparation and writing of *Endodontic Microsurgery*. His book should find its place in the library of any dentist or specialist interested in microendodontics and surgery.

Pierre Machtou, DDS, MS, PhD, FICD  
 Université Paris Diderot – Paris 7, France

## Dedication

**To my parents Antonio and Carmen, to whom I owe everything.**

To Dr Herbert Schilder (Boston), who introduced me to modern endodontics more than 20 years ago.

To my “endodontic father”, Dr Pierre Machtou (Paris), for infusing me with his love of endodontics and his great devotion to teaching.

To Dr Singcuk Kim (Philadelphia), who showed me the way to scientific endodontic microsurgery.

To Dr Guillermo Calleja and Dr Gilberto del Rosario (Madrid) for the SEM images of sutures.

To Dr Julio Galvez (Philadelphia) for his help in reviewing the final manuscript.

To my assistants Olga, Esperanza, MariAngeles and Begoña, for their help and care for me and my patients. To Jose Avelino and his lab team. To Gonzalo for his infographic work.

To Johannes Wolters and Thomas Pricker (Quintessence Verlag) for their confidence and patience with me.

# Contents

	<b>Introduction</b>	<b>1</b>
<b>1</b>	<b>Magnifying the Surgical Field with an Operating Microscope</b>	<b>5</b>
	Introduction	5
	The Microscope and the Loupe Compared	6
	The Loupe – The Microscope	
	The Microscope's Main Features	13
	Microscope Parts	14
	Eyepieces – Binoculars – Magnification Changer – Focusing Knob – Objective Lens – Beam Splitter – External Monitor or Co-observation Tube – Picture and Video Adapters – Digital Picture Camera – Video Camera	
	Advantages and Disadvantages of Using a Microscope	23
	Advantages – Disadvantages	
	Ergonomic surgical working positions	26
	Working Positions	28
	Golden Rules when Buying a Microscope	30
	Golden Rules to Get Started	31

<b>2</b>	<b>Presurgical Considerations</b>	<b>33</b>
	Introduction	33
	Indications and Contraindications	34
	Indications – Contraindications	
	Patient Considerations	45
	Patient Expectations – Patient Collaboration –	
	Medical History – Expense – Informed Consent	
	Surgeon Skills	47
<b>3</b>	<b>Endodontic Microsurgery Step by Step</b>	<b>49</b>
	Introduction	49
	Anesthesia	49
	Rationale – Technique	
	Flap Design	51
	Rationale – Rules of Flap Design – Flap Types	
	Incisions	57
	Elevation	61
	Retraction	63
	The Osteotomy Window	65
	Clinical Situation 1: Intact Cortical Bone Plate – Clinical	
	Situation 2: Perforation of the Cortical Bone Plate without	
	Periosteum – Clinical Situation 3: Perforation of the Cortical	
	Bone Plate with Periosteum – Clinical Case	
	Curettage	71
	Technique	
	Hemostasis	73
	History – Inducing Hemostasis – Topical Hemostatic Agents –	
	Recommendations	
	Apicoectomy	78
	Comment – Technique – Methylene Blue – Isthmus	
	Ultrasonic Retrocavity Preparation	89
	Ultrasonic Microtip Types – Microtip Materials – Tip Angulation	
	– Irrigation – Problems – Ultrasonic Files – Micromirrors	
	Drying	98
	Obturation	99
	Retrofilling Cement: Types, Selection and Techniques:	
	Amalgam · Zinc Oxide-eugenol (ZOE) Cements ·	

	Intermediate Restorative Material (IRM) · SuperEBA · Glass Ionomer Cement (GIC) · Gutta-percha · MTA Cement · Composite · Compomers – Summary	
	Suturing	110
	Types of Healing – Needles – Sutures: General Observations · Non-absorbable Sutures · Absorbable Sutures – Knots – Instruments – Technique Selection – Observations and Suggestions – Suture Removal	
<b>4</b>	<b>Postsurgical Considerations</b>	<b>133</b>
	Postsurgical Instructions	133
	Analgesics	134
	Non-narcotic Analgesics – Non-steroidal Anti-inflammatories – Narcotic Analgesics – Suggestions	
	Antibiotics	138
	Disinfectant Solutions	140
<b>5</b>	<b>Endodontics and Periodontics</b>	<b>143</b>
	Introduction	143
	Histological Considerations	144
	Endo–Perio Lesions Classification	150
	Endodontic disease – Endodontic Disease with Secondary Periodontic Involvement – Periodontal Disease – Periodontal Disease with Posterior Endodontic Involvement – The True Endo–Perio Lesion	
	False Endodontic Lesion with Periodontal Involvement	162
	Vertical Root Fracture (VRF): Etiology – Radiology – Probing – Sinus Tract – Typical Cases – Iatrogenic Perforations	
	Conclusions	169

<b>6</b>	<b>Treatment of Bone Defects in Apical Endodontic Microsurgery</b>	<b>175</b>
	Introduction	175
	Bone Defect Classification	176
	Large Bone Defects – Through-and-Through Defects – Apicomarginal Bone Defects	
	Clinical and Radiological Diagnostic Methods	179
	Traditional methods – Cone-beam Computed Tomography: Features of CBCT · Field of Vision · Collimation · Photograms · Gray Scale · Voxel Size · Sensor Type · Effective Dose Comparison · Potential Applications of CBCT in Endodontics	
	Guided Bone Regeneration	188
	Introduction – Barrier Membrane Characteristics: Biocompatibility – Cell Occlusiveness – Space-making Capability – Tissue Integration – Clinical Manageability – Membrane Types: Introduction · Non-absorbable Membranes · Absorbable Membranes – Membrane Exposition and Contamination	
	Bone Graft Materials and their Uses	196
	Autologous (Transplant within the same Patient) – Allografts (Transplant within the Same Species) – Xenografts (Cross-species Transplantation) – Alloplasts (Implantation of Synthetic Material)	
	Modification of the Flap Design	201
	Bone Defect Treatments	202
	Clinical Cases	202
	Clinical Case 1: AMBD (“old-style treatment”) – Clinical Case 2: AMBD (“current style”) – Clinical Case 3: TTBD – Clinical Case 4: AMBD + TTBD	
<b>7</b>	<b>Treatment of Bone Defects in Non-endodontic Microsurgery</b>	<b>217</b>
	Lateral Canals	217
	Presurgical Bone Defect Evaluation – Technique – Clinical Case 1 – Clinical Case 2 – Differential Diagnosis	
	External Resorption	222
	Presurgical Evaluation – Treatment	

Perforations	225
Introduction – Etiological Classification – Diagnosis of Perforation – Strategies for Iatrogenic Perforations: Waiting Time · Materials · Size and Shape · Location · Access · Prognosis	
Non-surgical Treatment of Perforations	233
Introduction – Processes – Clinical Case 3 – Clinical Case 4	
Surgical Treatment of Perforations	237
Indications – Contraindications – Clinical Case 5 – Clinical Case 6 – Clinical Case 7 – Clinical Case 8	
Root Resective Procedures	243
Introduction – Indications – Contraindications – Root Amputation – Hemisectioning – Assessment and Planning – Clinical Procedures: Root Canal Treatment · Resectioning Procedure · Extraction · Bone Graft · Final Restoration · Prognosis	
Intentional Replantation	252
Introduction – Indications – Contraindications – Clinical Case Selection – Technique – Postoperative Instructions – Reasons for Failure – Recommendations – Clinical Case 9	

## **8 Implantology** **269**

Introduction	269
Clinical Examination	270
Radiographic Examination	271
General Issues – Types of Examination	
Implant Placement	273
Planning	278
Implant Surgery	278
Rationale of the Immediate Implant	282
Indications – Advantages – Contraindications	
Graft Materials	285
Hard Tissue Grafts – Soft Tissue Grafts	
Factors Associated with Successful Immediate Implant Therapy	287
Bone Profile – Experience of the Clinician – Dehiscences – Infrabony Defects – Combined Defects	
Summary and Guide	
Maintenance Program	306

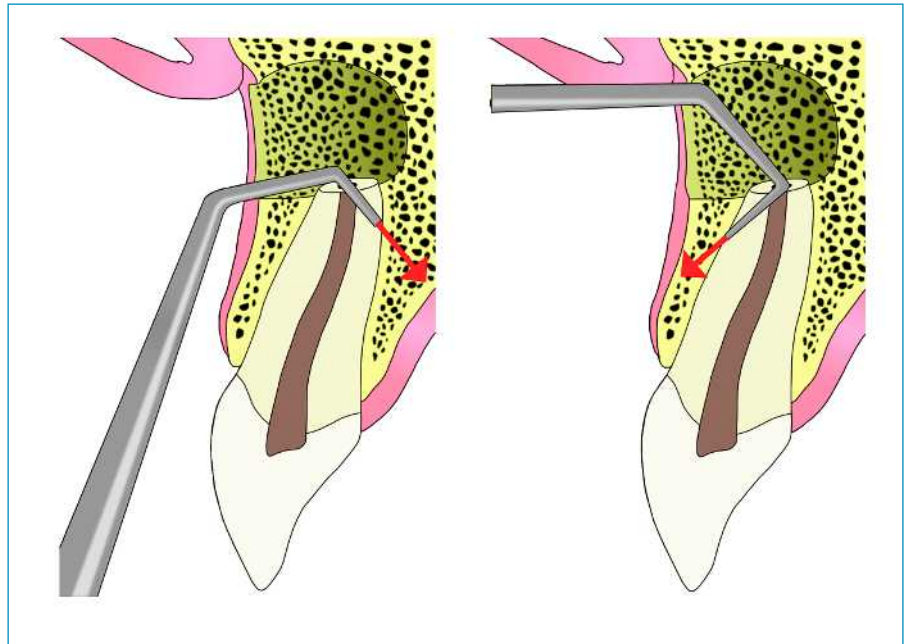
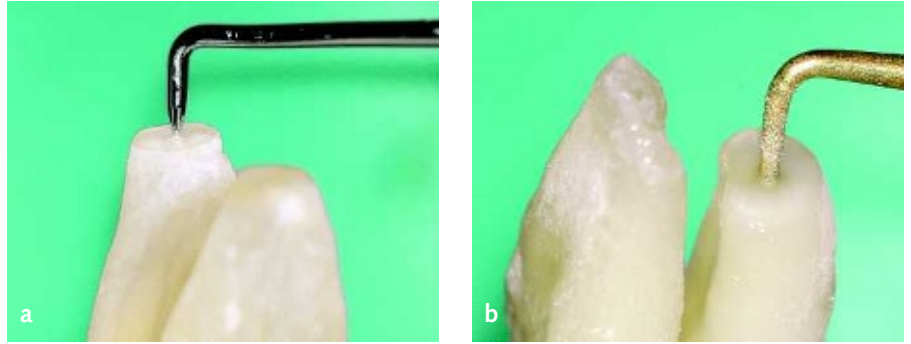


Endodontic Treatment versus Implant Position Statement	307
Endodontic Microsurgery and Implants	314
<b>9 Success Rate of Surgical Endodontics</b>	<b>319</b>
How Can Success be Defined? Histological Features – Radiological Features – Clinical Success	319
The Origins of Surgical Failure Presurgical Factors – Surgical Factors – Postsurgical Factors	322
Clinical case: Wrong Diagnosis	329
Comments on the Literature Success/Failure Rates – Method/Technique/Technology Used – Sample Size – Surgeon Experience and Skills – Study Design	330

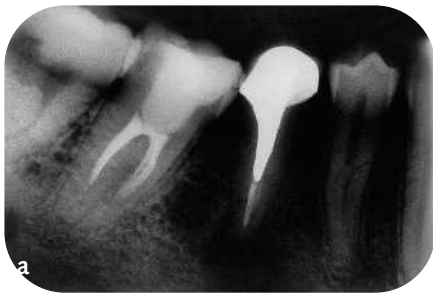

**Fig. 3-113** Standard tips (CT). The narrowest Slim Jim (SJ) tips should be used when dealing with fine apexes: mandibular incisors, premolars, etc.

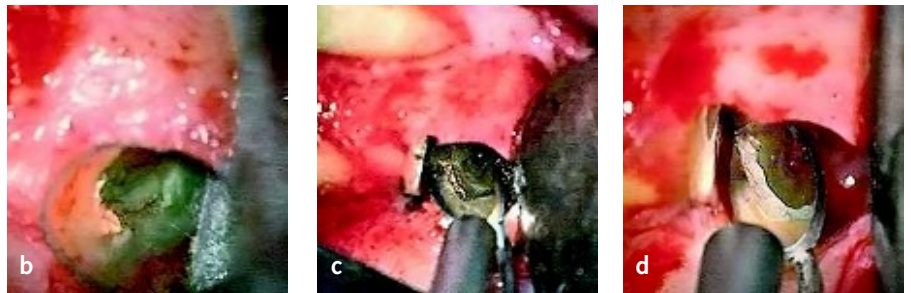
**Fig. 3-114** (top, right) (a) The thinner the remaining dentin walls after apicoectomy, the thinner the microtip must be. This is a Slim Jim microtip on a maxillary premolar root. (b) The thicker the dentin walls, the thicker the microtip can be without producing microfractures. This is a ProUltra microtip on the distal root of a mandibular molar.



**Fig. 3-115** Perforation of microcavity walls to the buccal surface can be sealed easily; but palatally, it is very difficult to seal (if noticed).



**Fig. 3-116** A failing endo treatment on a mandibular right second premolar with an unremovable coronal obstacles is referred for treatment. Appearance of earlier treatment seems to be correct in terms of length and obturation quality. After raising the flap and resecting the apex, a C-shaped canal was uncovered, prepared using Slim Jim microtips, and obturated with superEBA cement.

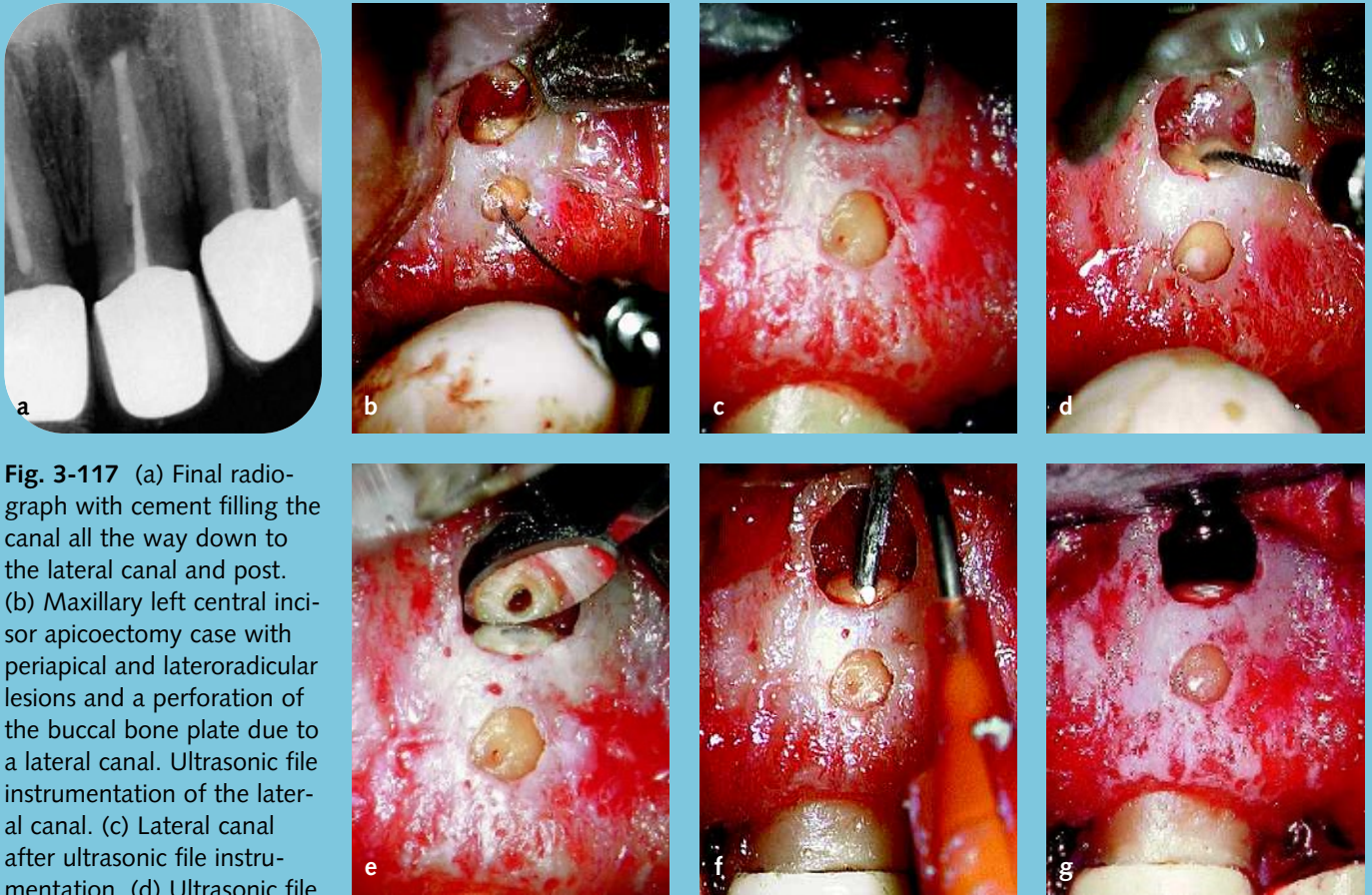


**“C-shaped” canal**

Cases with “C-shaped” canal anatomy should be prepared totally (Fig. 3-116).

**Facial burns**

Care must be exercised at all times to ensure that the shaft of a hot ultrasonic tip does not come into contact with the lip, cheek, or facial tissues<sup>72</sup>.

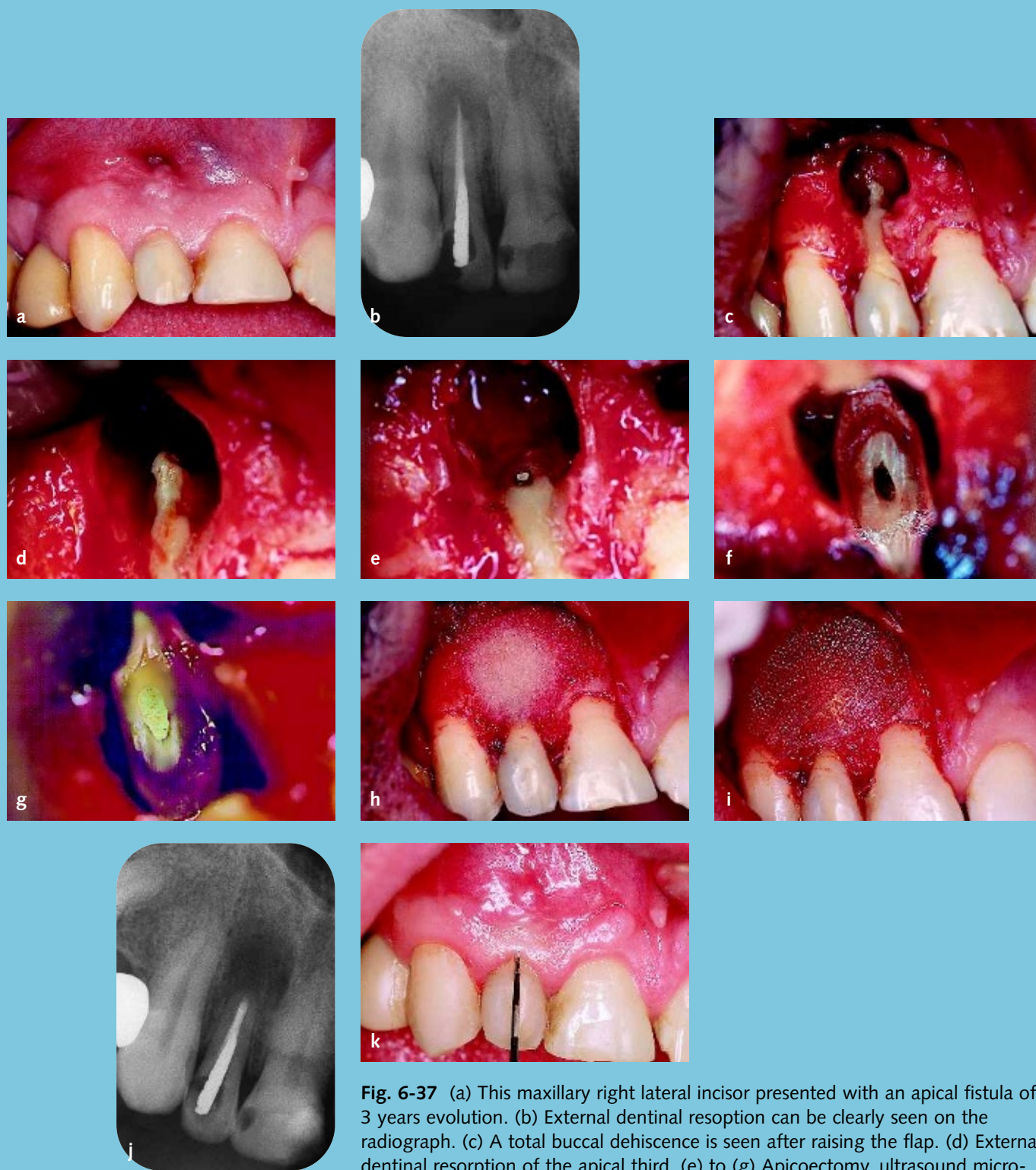


**Fig. 3-117** (a) Final radiograph with cement filling the canal all the way down to the lateral canal and post. (b) Maxillary left central incisor apicoectomy case with periapical and lateroradicular lesions and a perforation of the buccal bone plate due to a lateral canal. Ultrasonic file instrumentation of the lateral canal. (c) Lateral canal after ultrasonic file instrumentation. (d) Ultrasonic file instrumentation of the main canal. Note how a milky secretion is exiting from the lateral canal. (e) The most difficult part of the canal to clean is the buccal wall, so a 70–80-degree buccal angulation file is advised. (f) Obturation of the canal by injection of superEBA cement with with a Centrix jeringe needle. (g) The main and lateral canals sealed.

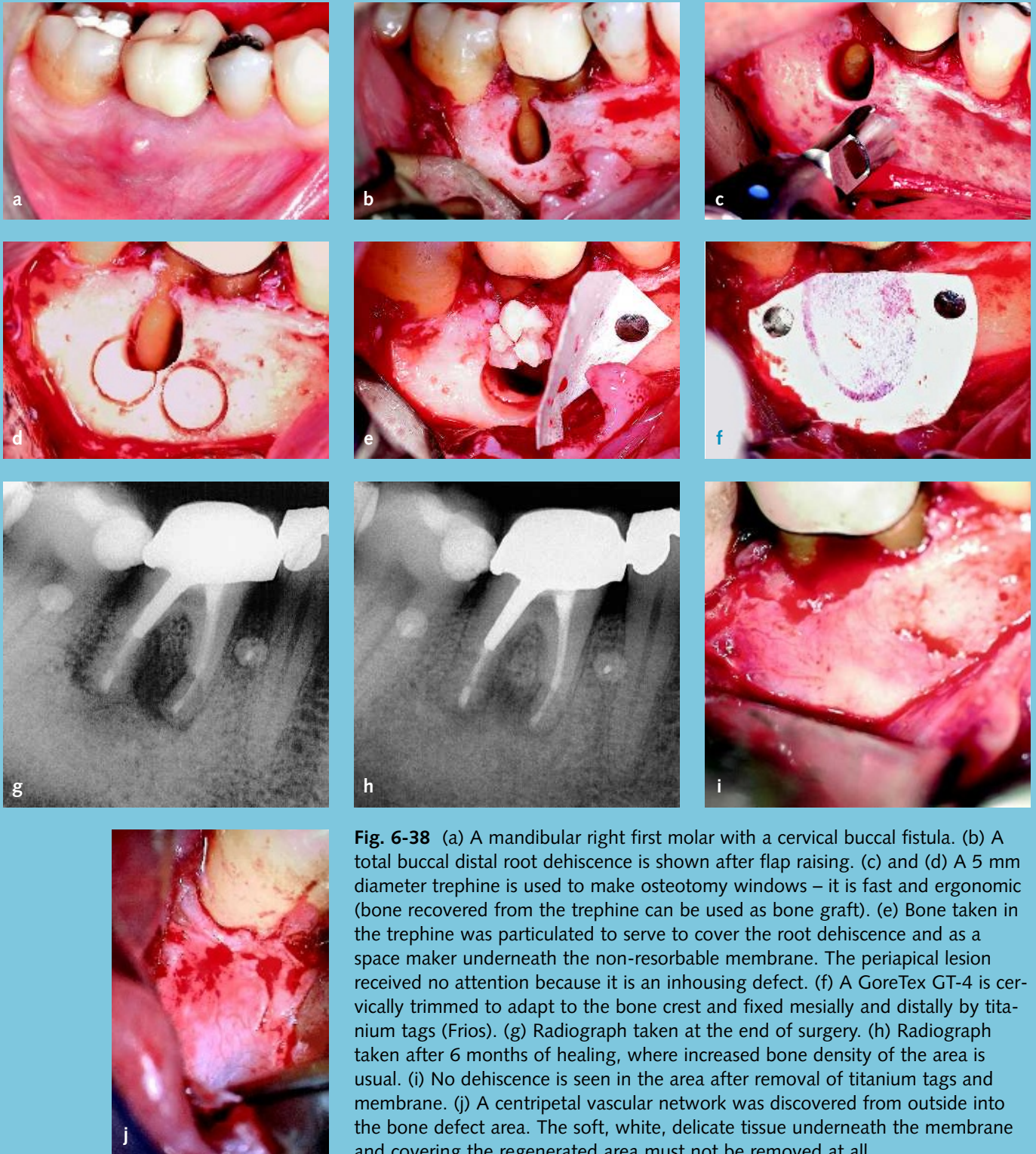
## Ultrasonic Files

Retrocavity depth should be 3 mm when the advisable previous non-surgical retreatment has been done. If this cannot be done, and the cleanliness status of the root canal system is unknown, it will be necessary to make a deeper retrocavity by means of an ultrasonic file: sometimes all the canal length up to the irremovable radicular obstacle<sup>73,74</sup>, post etc., or to the lateral canal that produces the bone lesion (Fig. 3-117).

The file size should be chosen to be neither too thin (vibration cavitation will not enlarge the canal) nor too thick (no vibration occurs). The file length should be chosen to prepare the canal all the way to the coronal obstacle, so most times a larger osteotomy window will be required (see Fig. 3-52).



**Fig. 6-37** (a) This maxillary right lateral incisor presented with an apical fistula of 3 years evolution. (b) External dentinal resorption can be clearly seen on the radiograph. (c) A total buccal dehiscence is seen after raising the flap. (d) External dentinal resorption of the apical third. (e) to (g) Apicoectomy, ultrasound microcavity preparation, and superEBA obturation. (h) DFDBA chips were used to cover the root dehiscence all the way down. (i) A Guidor resorbable membrane covering the bone graft, horizontally 2–3 mm beyond bone defect limits and vertically to the height of the surrounding bone crest and 2–3 mm below the gingival margin of the flap. (j) Radiographic appearance after surgery. (k) Probing depth at the dehiscence site after 6 months of healing.



**Fig. 6-38** (a) A mandibular right first molar with a cervical buccal fistula. (b) A total buccal distal root dehiscence is shown after flap raising. (c) and (d) A 5 mm diameter trephine is used to make osteotomy windows – it is fast and ergonomic (bone recovered from the trephine can be used as bone graft). (e) Bone taken in the trephine was particulated to serve to cover the root dehiscence and as a space maker underneath the non-resorbable membrane. The periapical lesion received no attention because it is an inhousing defect. (f) A GoreTex GT-4 is cervically trimmed to adapt to the bone crest and fixed mesially and distally by titanium tags (Frios). (g) Radiograph taken at the end of surgery. (h) Radiograph taken after 6 months of healing, where increased bone density of the area is usual. (i) No dehiscence is seen in the area after removal of titanium tags and membrane. (j) A centripetal vascular network was discovered from outside into the bone defect area. The soft, white, delicate tissue underneath the membrane and covering the regenerated area must not be removed at all.