

---

*Daniele Manfredini*

# **Current Concepts on Temporomandibular Disorders**

 **QUINTESSENCE PUBLISHING**

London, Berlin, Chicago, Tokyo, Barcelona, Istanbul, Milan, Moscow,  
New Delhi, Paris, Beijing, Prague, São Paulo, Seoul and Warsaw



---

# Preface

When the idea to bring together some of the most renowned experts in the field to give form to a work on the state-of-the-art knowledge of temporomandibular disorders (TMD) came to my mind, I was inspired to pursue that dream. But then I realized how difficult a task I was undertaking and doubts started to cloud my mind.

Classically, the TMD field has been characterized by a paradigmatic contrast between the guidelines provided by the scientific community and beliefs of clinical practitioners, who still look at dental occlusion as the main etiopathogenetic factor and the primary therapeutic target. The ambitious aim of this work is to keep on seeking a synthesis between these two cultures, as has already been attempted by some other recent textbooks on this subject. So the focus of all the contributors has been on the need to present scientifically sound information in a clinically useful manner.

This book will probably be one of the last in which the term “temporomandibular disorders” is used, since terminological specifications will hopefully be introduced in the near future, as soon as there is an improvement in knowledge about the pathophysiology of these disorders. Indeed, the absence of a validated pathophysiological model for many TMD symptoms has led to the adoption of this generic term to group together signs and symptoms with different etiopathogenesis and, more importantly, to adopt a symptomatic and common approach towards the management of diseases

of the temporomandibular joint and muscles. For this reason, the part of the book dedicated to etiology of TMD is the only one in which specific chapters are devoted to the supposedly different groups of disorders, namely muscle disorders, disc displacements, and arthrosis/arthrititis. The parts on diagnosis and management reflect the current view that the approach to TMD patients is seldom different for joint and muscle symptoms, to the point that only a minority of treatment modalities are exclusively indicated for a specific disorder.

Along with this underlying premise, the main thrust of the book is the medically based view of TMD, which cannot be considered pertinent to the dental profession alone.

All the chapters reflect the considerable efforts of the contributors to capture the reader's attention without abandoning their roles as academicians, scientists, and researchers. I have learnt that the greatest personalities are also the most modest ones, and this adventure has confirmed this for me. I have had the honor to work with 45 outstanding world-renowned authors in the TMD and orofacial pain field, and none of them has ever refused to exchange opinions, accept advice, or provide suggestions. To all of them I give my most grateful thanks for agreeing to be part of this project, one of the most exciting of my professional career to date.

Together we hope that our efforts will be appreciated by the heterogeneous community of TMD readers and practitioners.

---

*To Debora, Aurora, Giacomo*

*Love, Life, Smile*

---

# Contents

## Part I Fundamentals

- 1. Anatomy of the Temporomandibular Joint and Masticatory Muscles** ..... 3  
*A. Bermejo-Fenoll*
- 2. TMD Classification and Epidemiology** ..... 25  
*D. Manfredini and L. Guarda Nardini*
- 3. TMD as a Chronic Pain Disorder** ..... 41  
*T. Suvinen*

## Part II Etiology

- 4. Etiopathogenesis of Muscle Disorders** ..... 61  
*G.M. Murray and C. Peck*
- 5. Etiopathogenesis of TMJ Disc Displacements** ..... 81  
*D. Paesani*
- 6. Temporomandibular Joint Osteoarthritis** ..... 111  
*D.W. Nitzan and A. Roisentul*
- 7. Bruxism and Temporomandibular Disorders** ..... 135  
*D. Manfredini and F. Lobbezoo*
- 8. Future Perspectives in TMD Pathophysiology** ..... 153  
*R. Peretta and D. Manfredini*

## Part III Diagnosis

<b>9. Introduction to TMD Diagnosis</b> . . . . .	171
<i>D. Manfredini</i>	
<b>10. Clinical Assessment</b> . . . . .	179
<i>M. Schmitter</i>	
<b>11. Psychosocial Assessment</b> . . . . .	191
<i>D. Manfredini</i>	
<b>12. Imaging of the Temporomandibular Joint</b> . . . . .	207
<i>A. Petersson</i>	
<b>13. Instrumental Approach</b> . . . . .	223
<i>K. Baba, Y. Ono and G. T. Clark</i>	
<b>14. Fibromyalgia</b> . . . . .	237
<i>K. Sipilä</i>	
<b>15. Differential Diagnosis of Orofacial Pain</b> . . . . .	247
<i>R.M.A. Leeson</i>	
<b>16. Headache and Temporomandibular Disorders</b> . . . . .	263
<i>F. Mongini</i>	
<b>17. Relationship between Otologic and TMD Symptoms</b> . . . . .	275
<i>E.F. Wright</i>	
<b>18. Malocclusion and Body Posture</b> . . . . .	283
<i>A. Michelotti and M. Farella</i>	
<b>19. Perspectives in Clinical Diagnosis of Temporomandibular Disorders</b> . . . . .	295
<i>R. Emshoff</i>	

## Part IV Management

<b>20. Fundamentals of TMD Management</b> . . . . .	305
<i>D. Manfredini</i>	
<b>21. Behavioral Treatment Approaches to Temporomandibular Joint and Muscle Disorders</b> . . . . .	319
<i>R.J. Gatchel</i>	
<b>22. Physical Therapy</b> . . . . .	327
<i>P. Nicolakis, V. Fialka-Moser</i>	
<b>23. Pharmacologic Management</b> . . . . .	339
<i>C.M. Rizzatti-Barbosa and M.C. Ribeiro-Dasilva</i>	
<b>24. Occlusal Therapy of Temporomandibular Pain</b> . . . . .	359
<i>J.C. Türp and H.J. Schindler</i>	
<b>25. Placebo Effect</b> . . . . .	383
<i>G. Mauro, G.M. Macaluso, C.S. Greene, G. Goddard and E. Manfredi</i>	
<b>26. TMJ Arthrocentesis</b> . . . . .	393
<i>L. Guarda Nardini and G. Ferronato</i>	
<b>27. TMJ Major Surgery</b> . . . . .	403
<i>G. Dimitroulis</i>	
<b>28. Prosthetic Rehabilitation in TMD Patients</b> . . . . .	417
<i>J.A. De Boever, A. De Laat</i>	
<b>29. Orthodontics in TMD Management</b> . . . . .	429
<i>D.J. Rinchuse and S. Kandasamy</i>	
<b>30. Management of Bruxism</b> . . . . .	447
<i>E. Winocur and F. Lobbezoo</i>	
<b>31. Integration of Research into Clinical Practice</b> . . . . .	459
<i>D. Manfredini</i>	
<b>32. Ethical and Legal Considerations</b> . . . . .	469
<i>M.B. Bucci</i>	
<b>33. Treatment of TMD: Think Twice!</b> . . . . .	483
<i>F. Lobbezoo, C.M. Visscher and M. Naeije</i>	
<b>Index</b> . . . . .	487





---

# List of Contributors

*Kazuyoshi Baba DDS, PhD*  
Chair and Professor, Department of  
Prosthodontics, School of Dentistry, Showa  
University, Japan

*Ambrosio Bermejo-Fenoll MD, DDS, PhD*  
Professor, Department of Dermatology,  
Stomatology, Radiology and Physical  
Medicine, Faculty of Medicine and  
Odontology, University of Murcia, Spain

*Jan A De Boever DDS, DMD, PhD*  
Professor Emeritus, Gent University, Belgium

*Brady M Bucci MD*  
Forensic odontologist, private practice,  
La Spezia, Italy

*Glenn T. Clark DDS, MS*  
Professor, Division of Diagnostic Sciences,  
University of Southern California  
School of Dentistry, Los Angeles, USA

*Antoon De Laat DDS, PhD*  
Professor, Department of Oral and  
Maxillofacial Surgery, School of Dentistry, Oral  
Pathology and Maxillofacial Surgery, Catholic  
University of Leuven, Belgium

*George Dimitroulis MDSc, FDSRCS(Eng),  
FFDRCS(Irel), FRACDS(OMS)*  
Head of Maxillofacial Surgery, Department of  
Surgery, St Vincent's Hospital, University of  
Melbourne, Australia

*Rüdiger Emshoff Dr Med, Dr (H)*  
Associate Professor, University Clinic of Oral  
and Maxillofacial Surgery, Innsbruck Medical  
University, Austria

*Mauro Farella DDS, PhD*  
Assistant Professor, Orthodontics and TMD  
Clinic, Department of Dental, Oral and  
Maxillofacial Surgery, University of Naples  
Federico II, Italy

*Giuseppe Ferronato MD, DDS*  
Professor and Head, Department of Oral and  
Maxillofacial Surgery, University of Padova,  
Italy

*Veronika Fialka-Moser MD*  
Professor, Department of Physical Medicine  
and Rehabilitation, AKH Wien, Medical  
University of Vienna, Austria

*Robert J Gatchel PhD, ABPP*  
Professor and Chairman, Department of  
Psychology, College of Science, University of  
Texas at Arlington, USA

*Greg Goddard DDS*  
Associate Clinical Professor (retired),  
University of California at San Francisco, USA

*Charles S Greene DDS*  
Clinical Professor and Director of Orofacial  
Pain Studies, Department of Orthodontics,  
College of Dentistry, University of Illinois in  
Chicago, USA

*Sanjivan Kandasamy BDS, BScDent,  
DocClin-Dent, MOrthoRCS*  
Senior Lecturer, Department of Orthodontics,  
Dental School, University of Western  
Australia, Perth, Australia

*Rachel M A Leeson BDS, MSc, PhD, FDS,  
RCS, FHEA*  
Specialist in Oral Surgery, Maxillofacial and  
Oral Surgery Department, Eastman Dental  
Hospital, University College London

*Frank Lobbezoo DDS, PhD*  
Professor, Department of Oral Kinesiology,  
Academic Centre for Dentistry Amsterdam  
(ACTA), University of Amsterdam, and VU  
University Amsterdam, The Netherlands

*Guido M Macaluso MD, DDS, MDS*  
Professor, Section of Odontostomatology,  
Faculty of Medicine, University of Parma, Italy

*Edoardo Manfredi DDS*  
Researcher, Section of Odontostomatology,  
Faculty of Medicine, University of Parma, Italy

*Daniele Manfredini DDS*  
Visiting Professor, TMD Clinic, Department of  
Maxillofacial Surgery, University of Padova,  
Italy

*Giovanni Mauro MD, DDS, PhD*  
Visiting Professor, Section of  
Odontostomatology, Faculty of Medicine  
University of Parma, Italy

*Ambra Michelotti MD, DDS, PhD*  
Professor, Orthodontics and TMD Clinic,  
Department of Dental, Oral and Maxillofacial  
Surgery, University of Naples Federico II, Italy

*Franco Mongini MD*  
Professor and Director, Section for  
Headache and Facial Pain, Department of  
Clinical Pathophysiology, University of Torino,  
Italy

*Greg M Murray BDS, MDS, PhD, FRACDS*  
Professor, Faculty of Dentistry, University of  
Sydney, Australia

*Machiel Naeije PhD*  
Biophysicist, Professor and Chair, Department  
of Oral Kinesiology, Academic Centre for  
Dentistry Amsterdam (ACTA), University of  
Amsterdam, and VU University Amsterdam,  
The Netherlands

*Luca Guarda Nardini MD, DDS*  
Visiting Professor and responsible for TMD  
Clinic, Department of Maxillofacial Surgery,  
University of Padova, Italy

*Peter Nicolakis MD*  
Professor, Department of Physical Medicine  
and Rehabilitation, AKH Wien, Medical  
University of Vienna, Austria

*Dorrit W Nitzan DMD*  
Professor, Department of Oral and  
Maxillofacial Surgery, Faculty of Dental  
Medicine, Hebrew University-Hadassah  
School of Dental Medicine, Jerusalem, Israel

*Yasuhiro Ono DDS, PhD*  
Assistant Professor, Department of  
Prosthodontics, School of Dentistry, Showa  
University, Japan

*Daniel Paesani DDS*  
Professor, School of Dentistry, University of  
Salvador/AOA, Buenos Aires, Argentina

*Christopher C Peck BDS, MScDent, PhD*  
Associate Professor, Faculty of Dentistry,  
University of Sydney, Australia

*Redento Peretta MD, DDS, PhD*  
Visiting Professor, Department of Maxillofacial  
Surgery, University of Padova, Italy

*Arne Petersson DDS, Odont dr*  
Professor, Department of Oral and  
Maxillofacial Radiology, Faculty of  
Odontology, Malmö University, Sweden

*Margarete Cristiane Ribeiro-Dasilva DDS, MS,  
PhD*  
Postdoctoral Fellow, College of Dentistry,  
University of Florida, USA

*Donald J Rinchuse DMD, MS, MDS, PhD*  
Clinical Professor of Orthodontics, School of  
Dental Medicine, Department of  
Orthodontics, University of Pittsburgh, USA

*Celia Marisa Rizzatti-Barbosa DDS, MS, PhD*  
Professor, Department of Prosthesis and  
Periodontology, Dental College of Piracicaba,  
State University of Campinas (Unicamp), Brazil

*Alejandro Roisentul DDS*  
Head, Unit of Oral and Maxillofacial Surgery,  
Ziv Governmental Hospital, Safed, Israel

*Hans J Schindler DDS, Dr Med Dent Habil*  
Associate Professor, Department of  
Prosthodontics, University of Heidelberg, and  
Biomechanics Research Group, University of  
Karlsruhe, Germany

*Marc Schmitter DMD*  
Professor, Department of Prosthodontics,  
Dental School, University of Heidelberg,  
Germany

*Kirsi Sipilä DDS, PhD*  
Senior Lecturer, Department of  
Stomatognathic Physiology and Prosthetic  
Dentistry, Institute of Dentistry, University of  
Oulu, Finland

*Tuija Suvinen DDS, PhD*  
Docent and Senior Scientist, Department of  
Stomatognathic Physiology, Institute of  
Dentistry, University of Turku, Finland

*Jens C Türp DDS, Dr Med Dent Habil*  
Professor, Clinic for Reconstructive Dentistry  
and Temporomandibular Disorders, Dental  
School, University of Basel, Switzerland

*Corine M Visscher PT, PhD*  
Epidemiologist, Assistant Professor,  
Department of Oral Kinesiology, Academic  
Centre for Dentistry Amsterdam (ACTA),  
University of Amsterdam, and VU University  
Amsterdam, The Netherlands

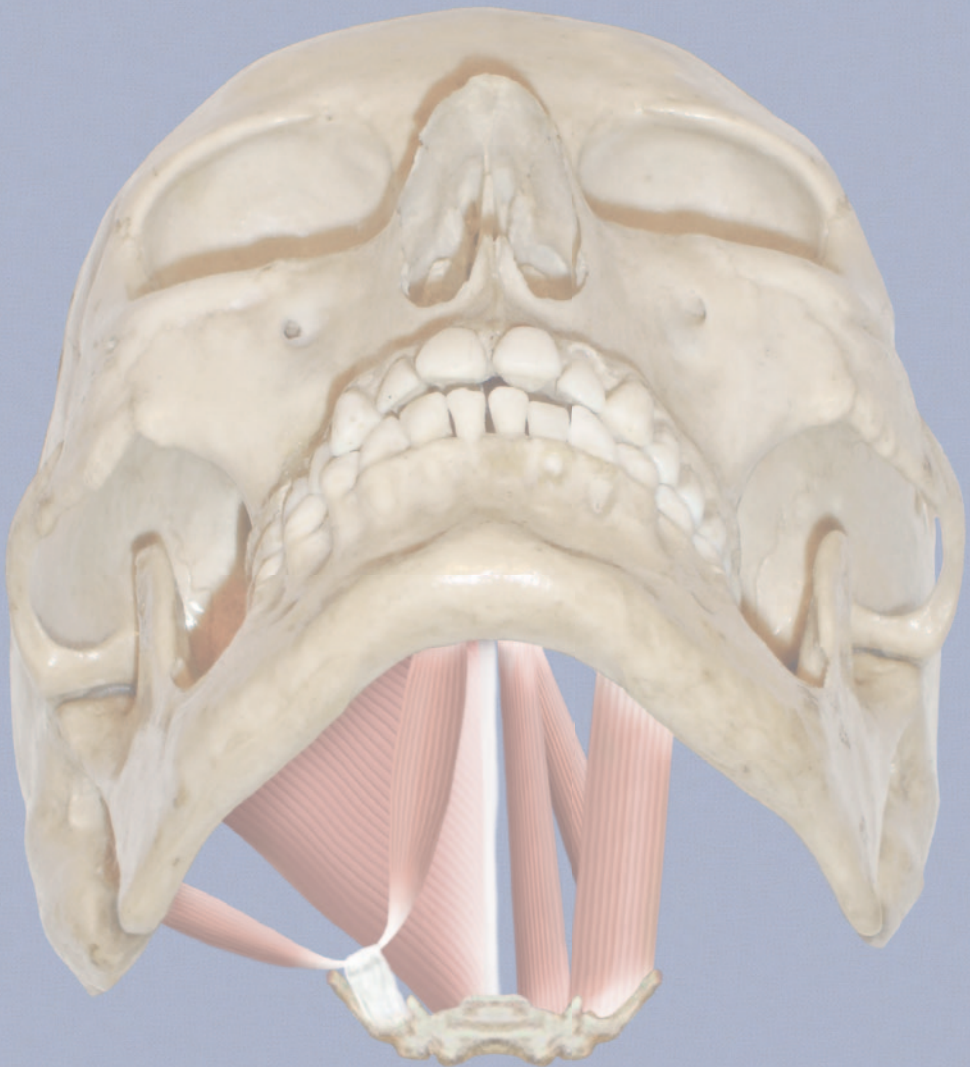
*Ephraim Winocur DMD*  
Director, Orofacial Pain Clinic, Goldschleger  
School of Dental Medicine, University of Tel  
Aviv, Israel

*Edward F Wright DDS, MS*  
Associate Professor, Department of  
Restorative Dentistry, University of Texas  
Health Science Center at San Antonio, USA



# PART I

# FUNDAMENTALS



**Table 8-2** Elements in biomechanical analysis of the temporomandibular joint.

Element	Characteristics	Condyle	Glenoid fossa	Disc
Body	Geometry	Section	Height	Convexity
	Material	Length bone	Depth bone	Fibrocartilage
Load features	Force vectors	Static Dynamic fatigue cycles		
Systems of body constraint	Degrees of freedom			

venience, in the remaining sections of the chapter, a brief description of the differences between forces exerted during function and during parafunction will be provided.

In addition, another element that should be introduced in the analysis is the number of degrees of freedom that characterize condylar movements under loading conditions.

In the following sections, the two conditions leading to joint overload, ie structural defect of the joint or abnormal joint load, will be described in detail with a focus on the mechanisms of load transfer on the joint tissues.

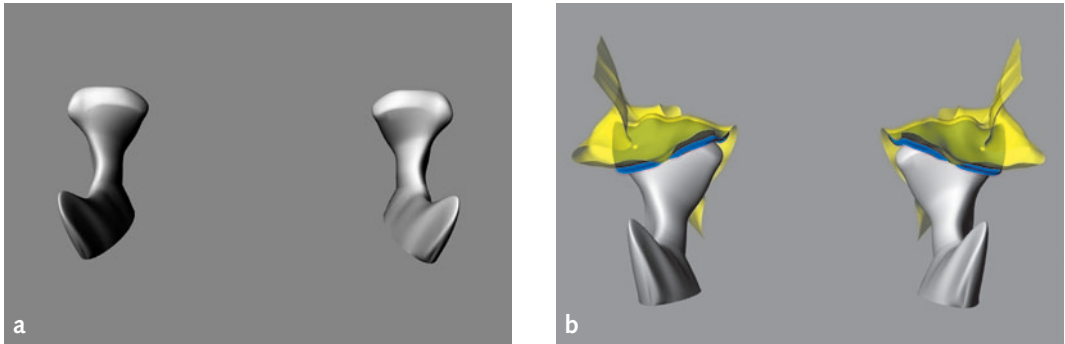
## Morphology of the Structurally Defective TMJ

There is much debate about the definition and description of the normal condylar morphology, and the many three-dimensional reconstructions proposed over the years, despite their appeal, can only be considered speculative (Figs 8-1a to 8-1c).

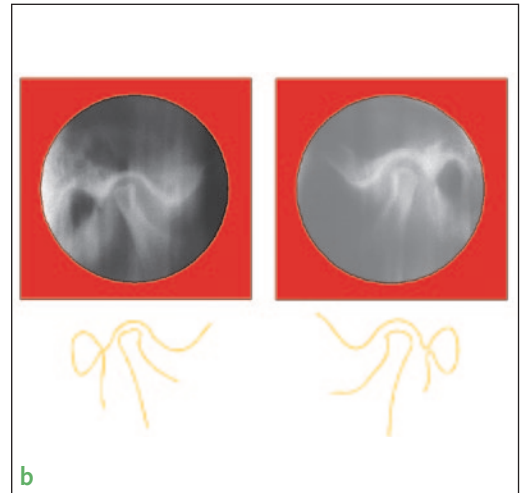
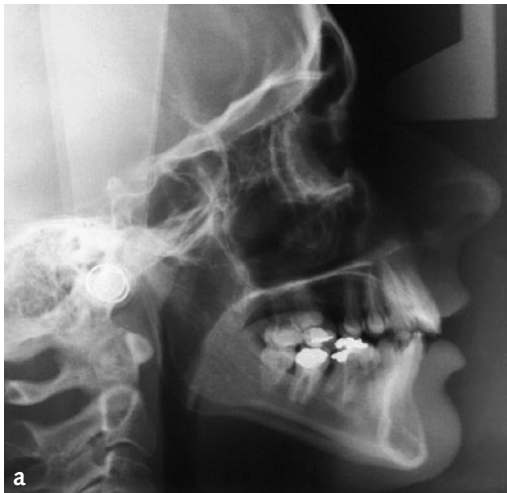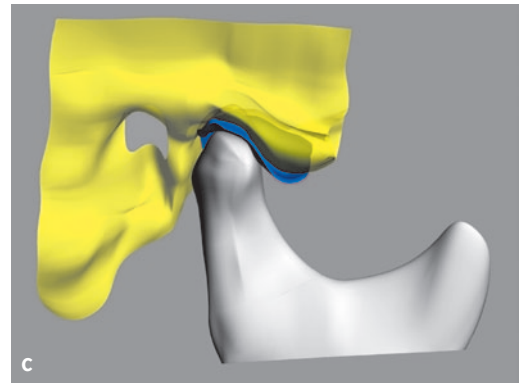
Thus, the identification of a typical joint morphology that is not suitable to bear loads has to start with the consideration and combination of both engineering and medical aspects. There is a considerable amount of orthodontic and maxillofacial literature showing that subtle, short, and posteriorly sloping condyles are a risk factor for the development of degenerative changes within the TMJ.<sup>30,31</sup> From a clinical viewpoint, such observations are well known

to maxillofacial surgeons who have treated skeletal class II patients with a mandibular advancement. Post-surgically, the stretching of the suprahyoid muscles induces a strong tensile force in the muscle, which is a risk factor for degenerative joint disease in those patients who have condyles with such structural characteristics.<sup>32</sup> Similar consequences may be seen in such patients also after surgery for internal mandibular ramus fixation.<sup>33,34</sup> These observations have contributed to the question of whether the so-called “idiopathic condylar resorption”, which shares many features with the other degenerative changes described as osteoarthritis,<sup>35</sup> is actually a long-term consequence of orthognathic surgery performed in patients with a peculiar condylar morphology. In summary, a small condyle is morphologically at risk of developing degenerative changes if it is exposed to excessive loads as a consequence of orthognathic surgery (Figs 8-2a, 8-2b).

And what about such a condylar morphology in patients who do not undergo orthognathic surgery? This question may find an answer in a philosophical analysis of the TMD–occlusion relation. As reported in many other sections of this book, studies on this issue have shown a weak association between TMD and occlusion, mainly in cases of gross dental occlusal abnormalities, such as a large horizontal overlap, ie overjet, and a decreased vertical overlap, ie overbite.<sup>36,37</sup> The main shortcoming of any investigation trying to assess the relation between occlusion and TMD is the absence of any assessment of the skeletal morphology, the evaluation of which should be of much interest



**Fig. 8-1a–c** Example of normal condylar position and joint morphology (tomography-derived three-dimensional model, DICOM).



**Fig. 8-2a, b** Lateral cephalometric radiograph, and corrected oblique transcranial radiographs and tracings of small condyles in a patient with a large horizontal overlap.

should be easy to learn, cost-effective, internationally accepted, available in different languages, and continually improving. Thus, on the one hand, non-essential features should be eliminated, and on the other, essential features should be emphasized and must not be eliminated. However, many systems emphasize physical findings and disregard psychosocial variables, although the importance of these variables in the development and maintenance of (painful) TMD has been demonstrated. Additionally, the identification of other clinical examination procedures is challenging and for some diagnostic systems, little is known about the scientific characteristics (reliability etc.).

In the following sections, several aspects of a clinical TMD examination are described. For an instrumental approach to TMD see Chapter 13.

## Dental/Medical History

In TMD patients, special attention should be paid to the history as important information can be gathered. Beside the knowledge of trauma<sup>9</sup> and other potentially harmful events,<sup>10</sup> the history taking might uncover valuable information about the onset of the TMD, its progression, and other particular information about the patient.<sup>11</sup> This information could enhance the clinical findings and lead to a more reliable diagnosis, and could consequently help to plan the most effective therapy concept. Thus, enough time should be provided for this important aspect in the clinical assessment of TMD.

## Palpation of the Muscles

The assessment of pain during the palpation of masticatory muscles is an important aspect in diagnosing myofascial pain. Thus, almost all available clinical examination protocols include the palpation of jaw muscles, although the number and the location of the included palpated muscles are different. Some of the

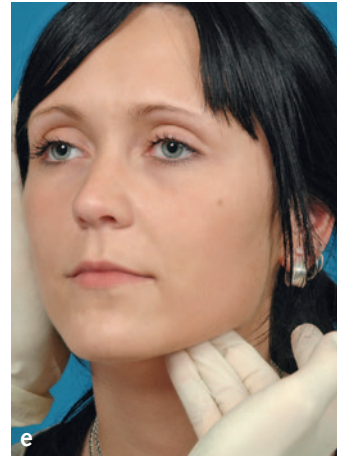
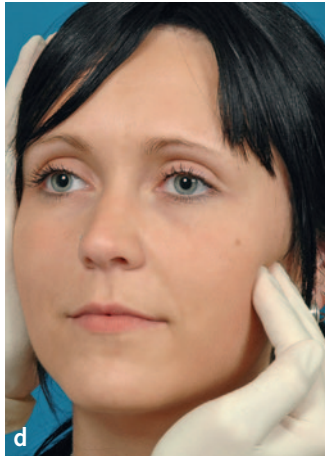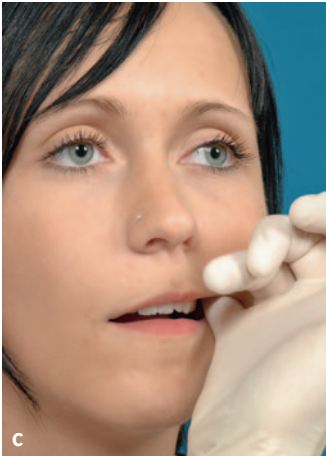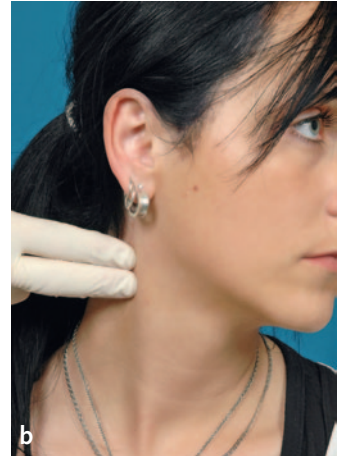
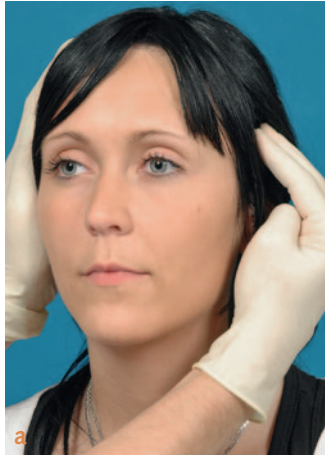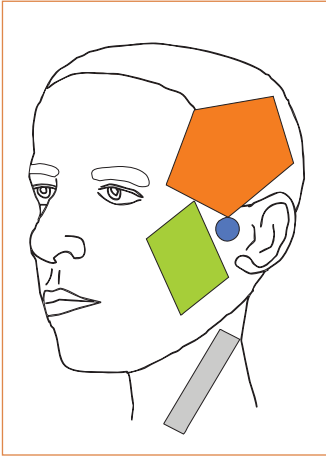
most important muscles which are included in almost all examination protocols are depicted in Figure 10-3. The palpation techniques (including pressure etc.) are quite different. (Fig. 10-4 shows palpation of the different muscles being carried out.) These factors confound the comparability of different examination protocols with respect to muscular findings. Moreover, some examination protocols recommend palpating the lateral pterygoid muscle, which is not directly palpable.<sup>12</sup>

Several studies have assessed the reproducibility of the muscle palpation and found acceptable to good agreement between the examiners,<sup>13-15</sup> although the reliability of the palpation of intraoral muscles might be lower than for extraoral muscles. However, it has also been demonstrated that calibration improves the reliability<sup>14</sup> of standardized clinical examination procedures. Another study found that in this scenario, the calibration of the examiners is more important than professional experience.<sup>5</sup> Thus, training on letter scales (Fig. 10-5) is recommended; retraining of examiners might improve the reliability even more.<sup>4,16</sup> The use of pressure algometers (Fig. 10-6) has been assessed in several studies and it seems to improve the reliability of the palpation,<sup>17,18</sup> justifying the use of algometers in clinical and experimental studies.

## Joint Palpation

Pain on palpation might be an indicator of a pathologic process in the temporomandibular joint and is included in several TMD examination protocols (Fig. 10-7, Fig. 10-8). The results for reliability are comparable with those for muscle palpation in studies. However, the differentiation between muscle and joint pain might be difficult for the patient because of the proximity of the temporomandibular joint and nearby muscles<sup>19</sup> and the presence of trigger points.<sup>20</sup> Thus, the results of palpation have to be interpreted with great care.





**Fig. 10-3** (top left) Location of the most important muscles that are included in an examination protocol for TMD.

**Fig. 10-4a-e** Palpation of the different jaw muscles included in a TMD clinical examination.



**Fig. 10-5** Calibration of palpation pressure using letter scales.



**Fig. 10-6** Pressure algometers may be useful tools to improve the reliability of muscle palpation.